

X-Ray Interpretation

Michigan Society for Respiratory Care

Fall Conference 2015

Rob Wonnacott MSN, RN, CCRN

University of Michigan Medical Center

Objectives

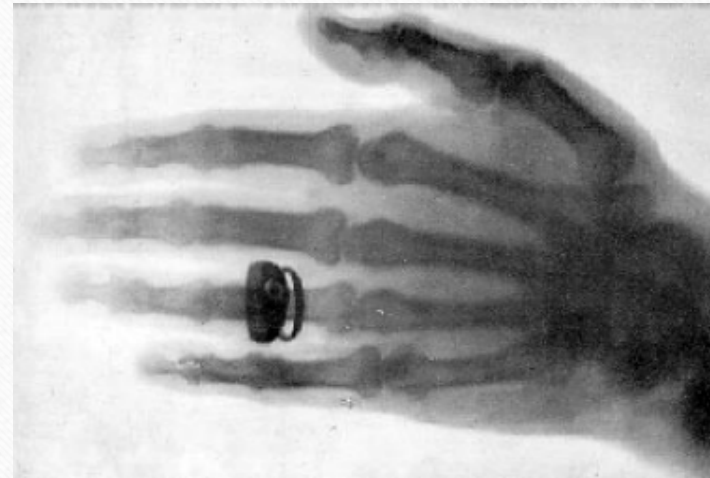- Background
- Types
- Technical qualities
- ABCDEF Mnemonic
- Case Studies
- Q&A

Family

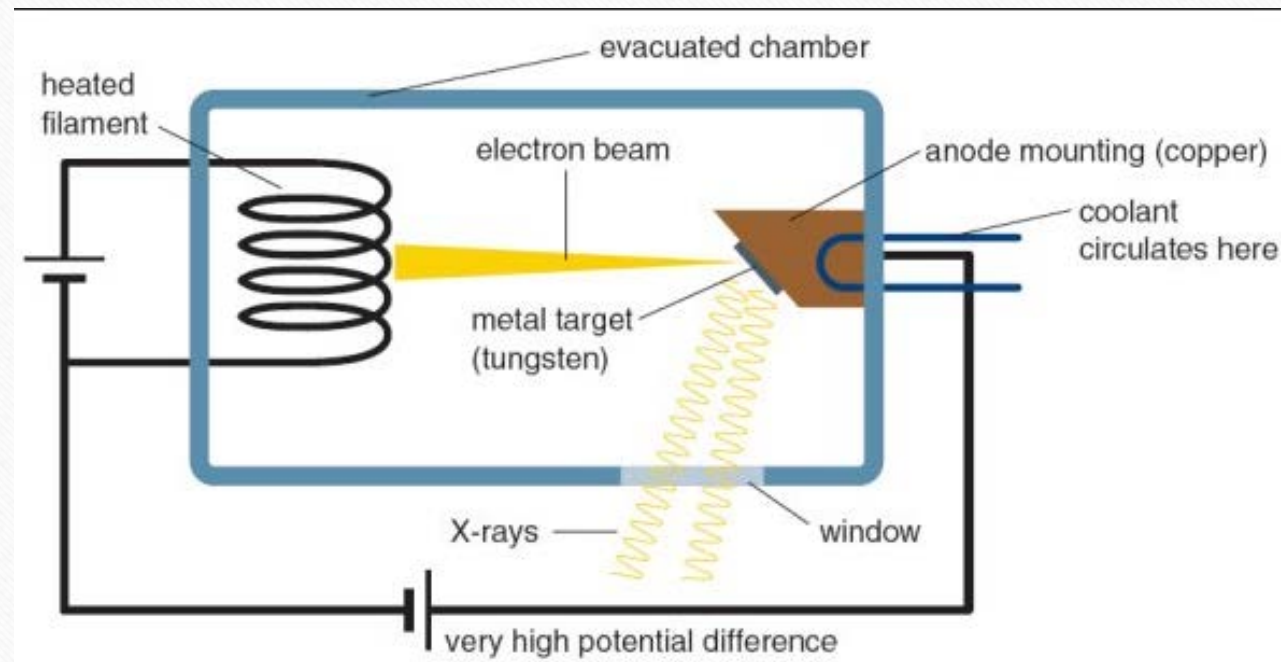


History

- By accident in 1895 by German scientist Wilhelm Conrad Roentgen
- Was able to see opaque items such as bones and foreign bodies
- First x-ray made public Jan 23 1896
- Used in 40 & 50's to fit shoes



How it works



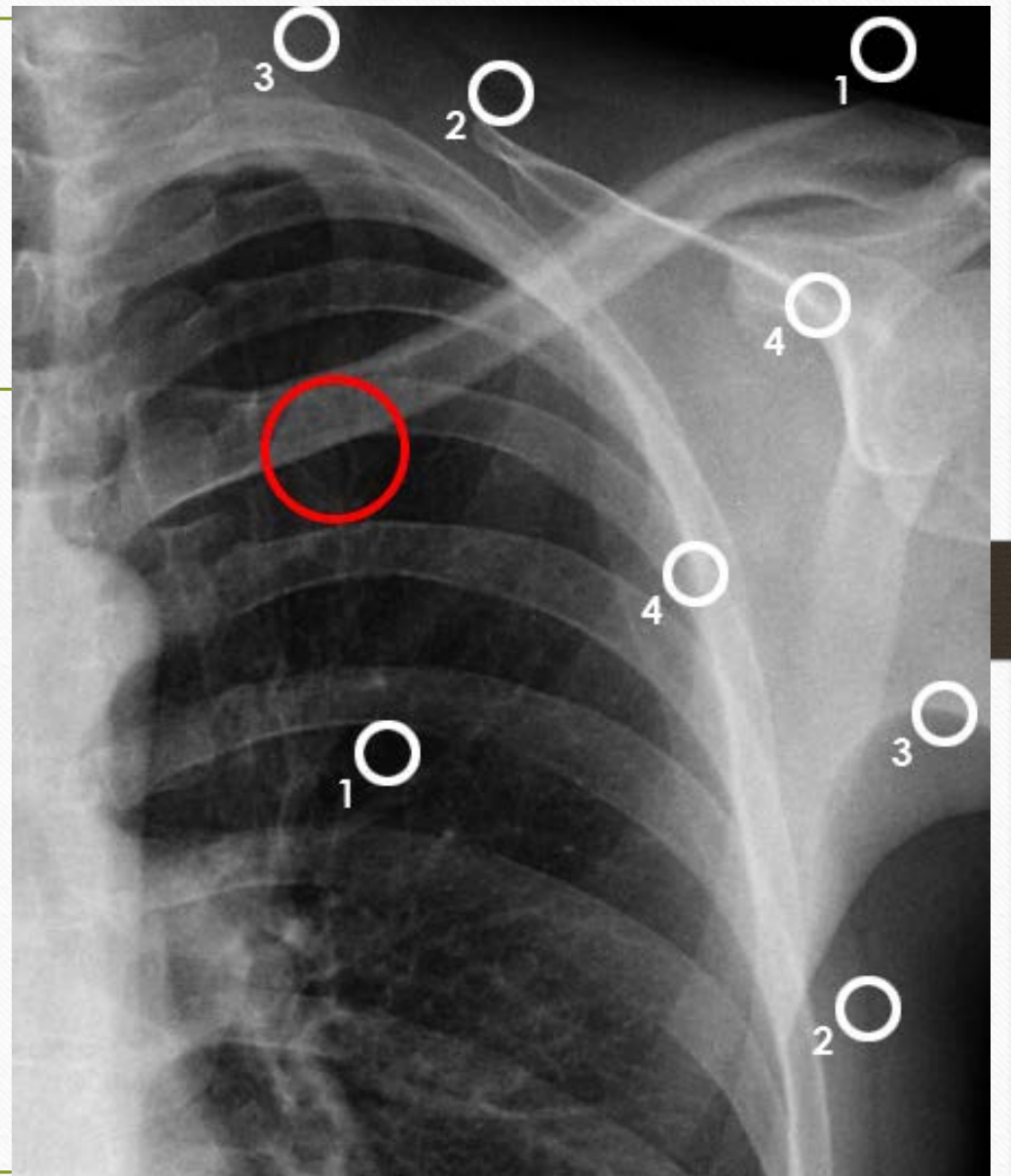
The 5 Colors



Tissue Densities

Key points

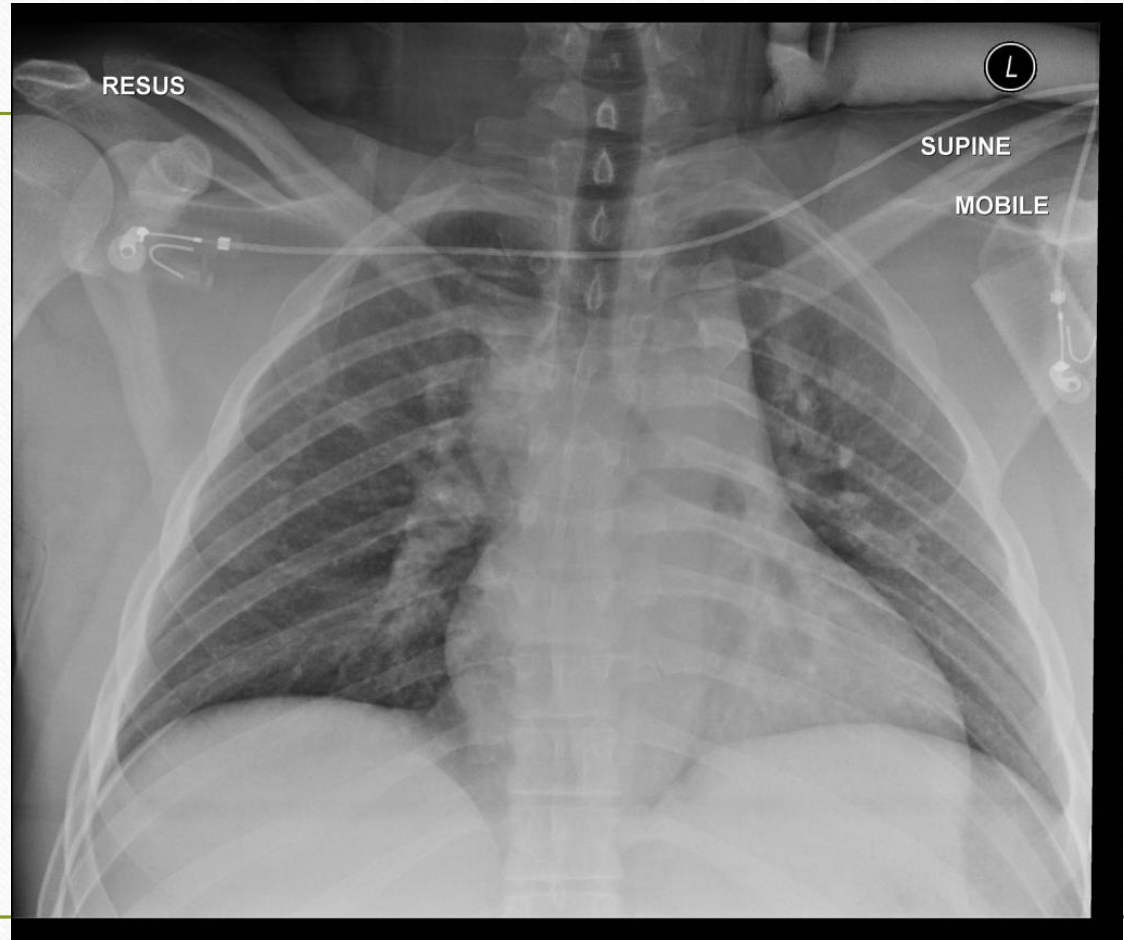
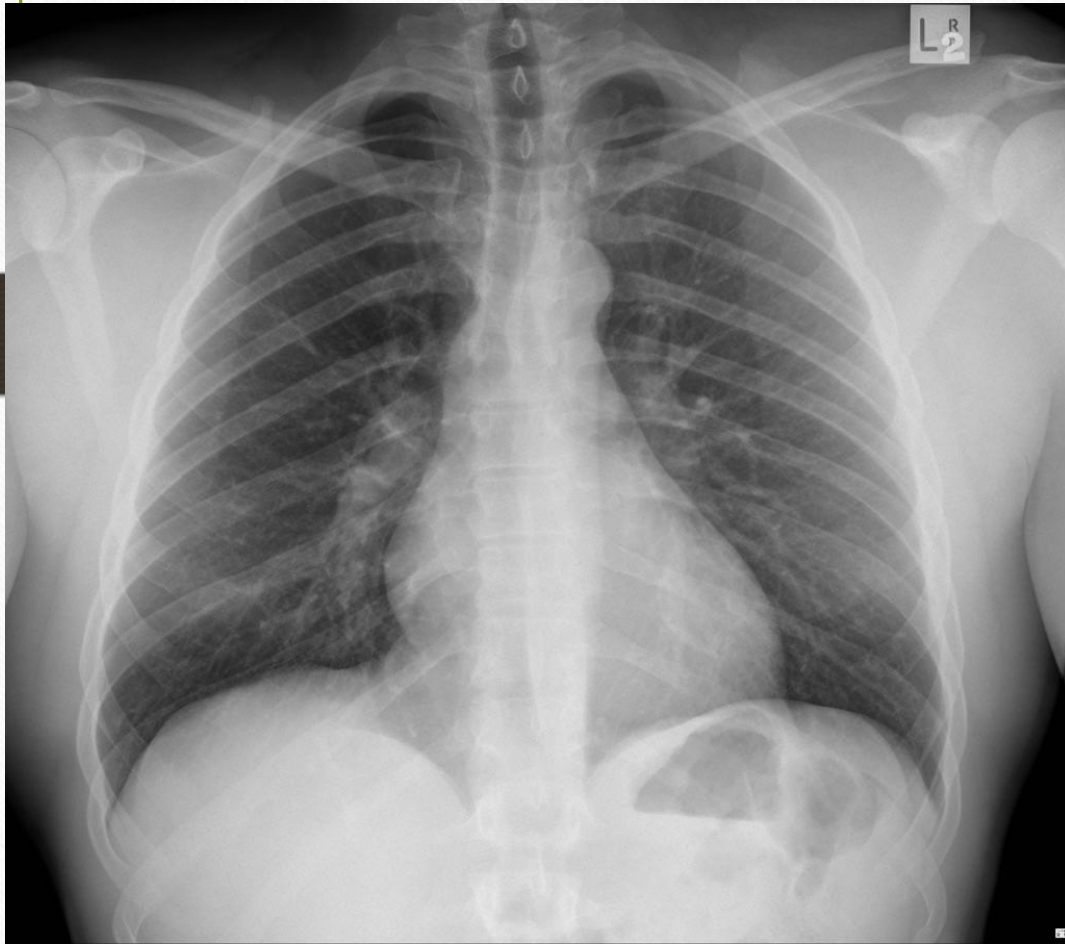
- ◆ 1 - Air/Lung
- ◆ 2 - Fat (layer between soft tissues)
- ◆ 3 - Soft tissue
- ◆ 4 - Bones



Position

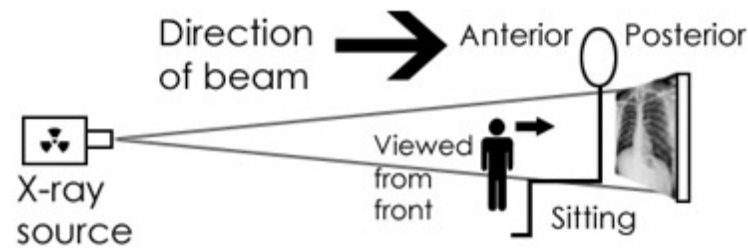
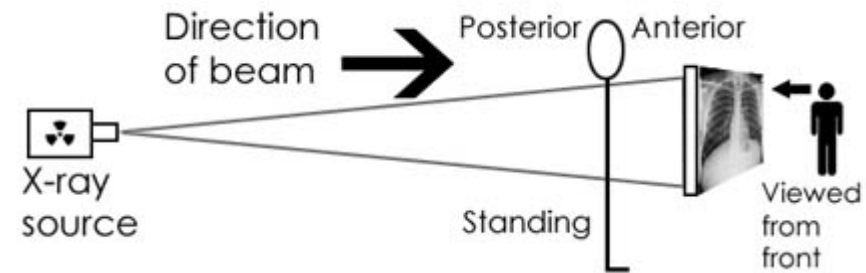
- AP – anteriorposterior
- PA – posteroanterior
- LAT – lateral
- Supine
- Upright

Positioning Example 1



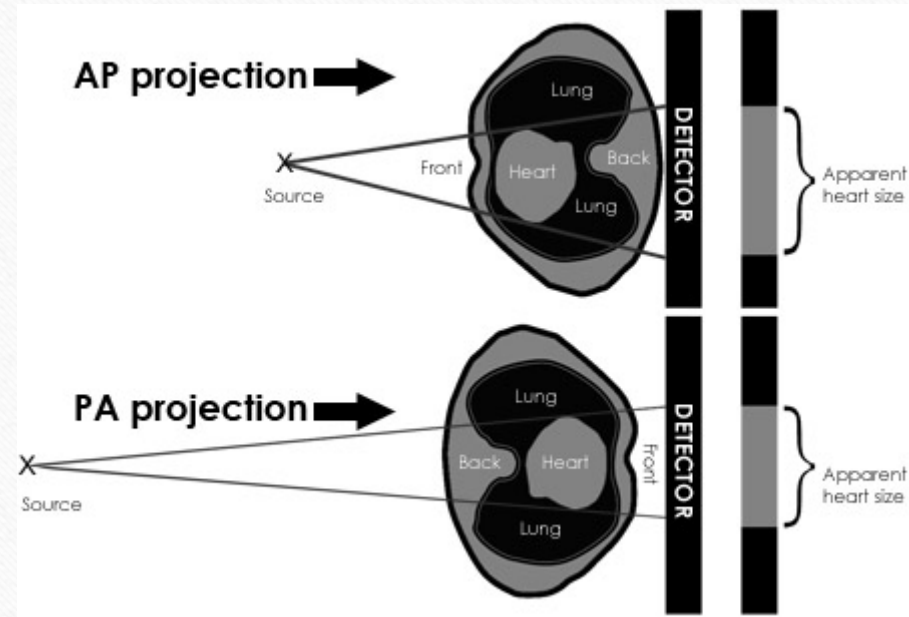
Why the difference

- Project a cone shape image
- Converts 3D to 2D
- Big impact on what really stands out.



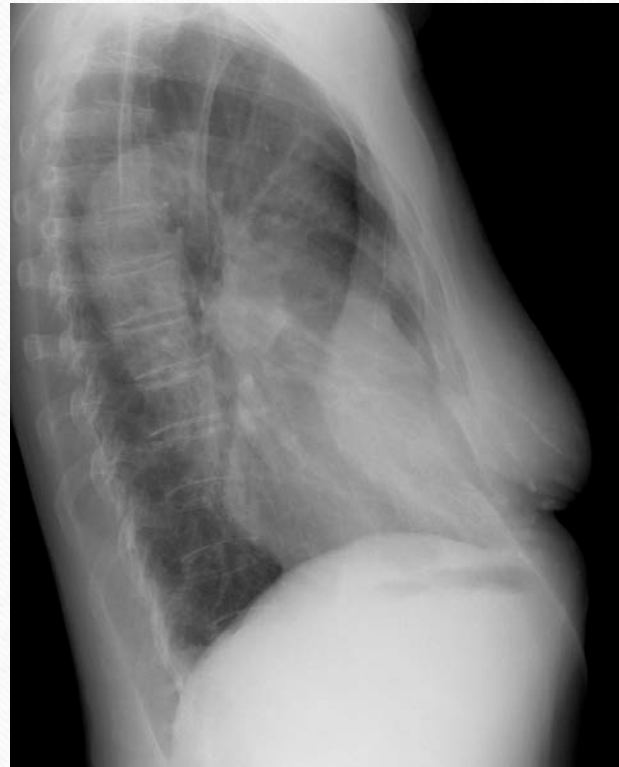AP vs PA

- Distance plays a big part!
- AP 40 inches (optimal)
- PA 70 inches (optimal)
- PA is industry standard



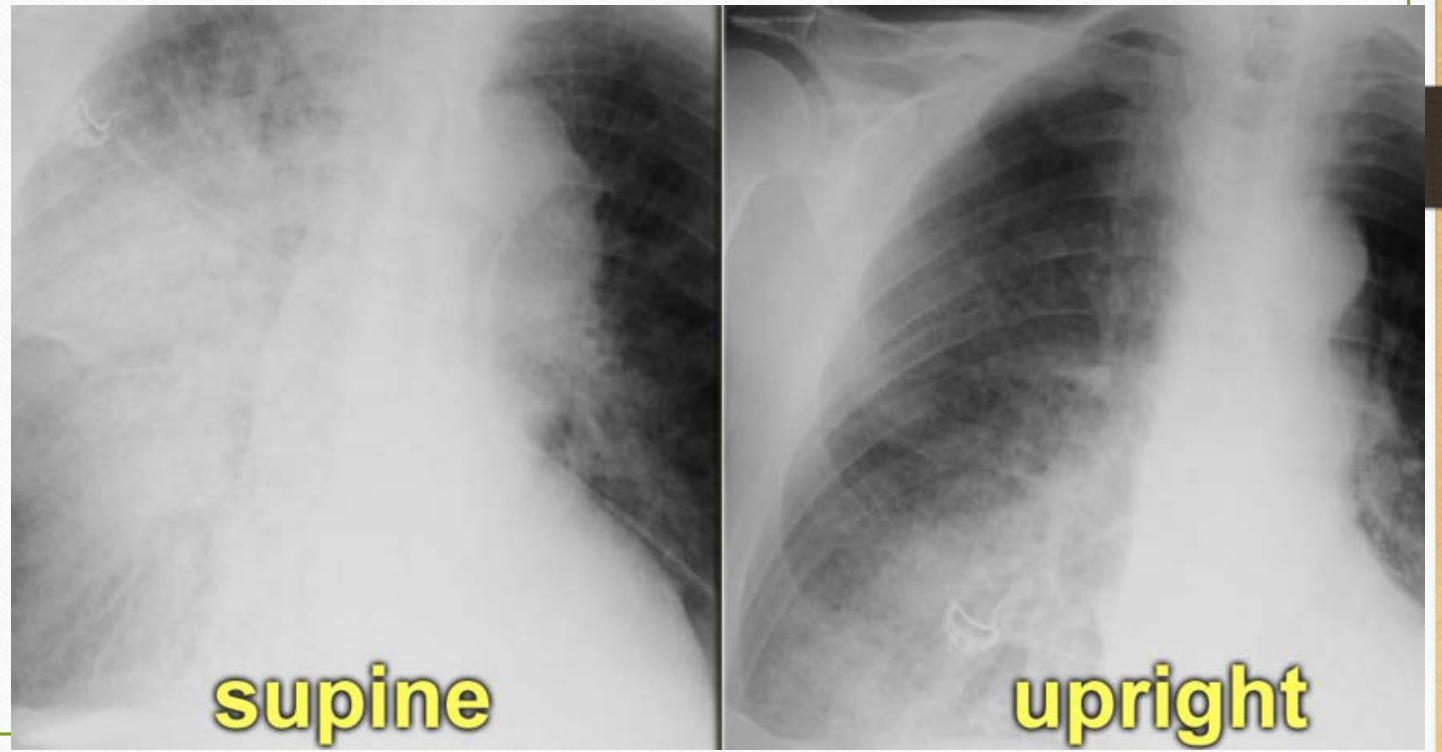
Lateral views

- Clarifying of significant finding
- Should not be routinely done



Supine vs Upright

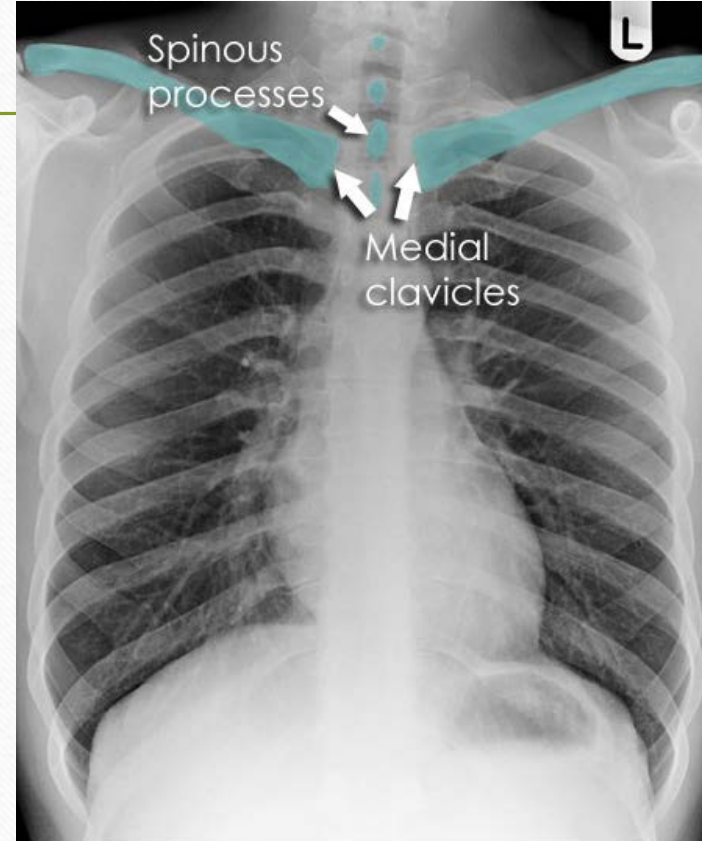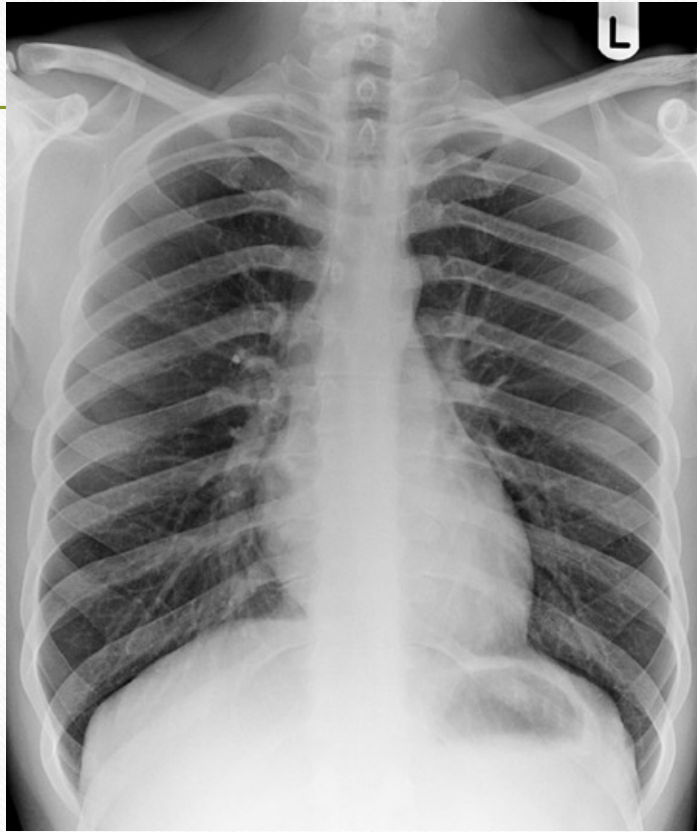- Used primarily to assess chest fluid levels.
- Supine allows for full expansion of lungs
- Standard for CXR



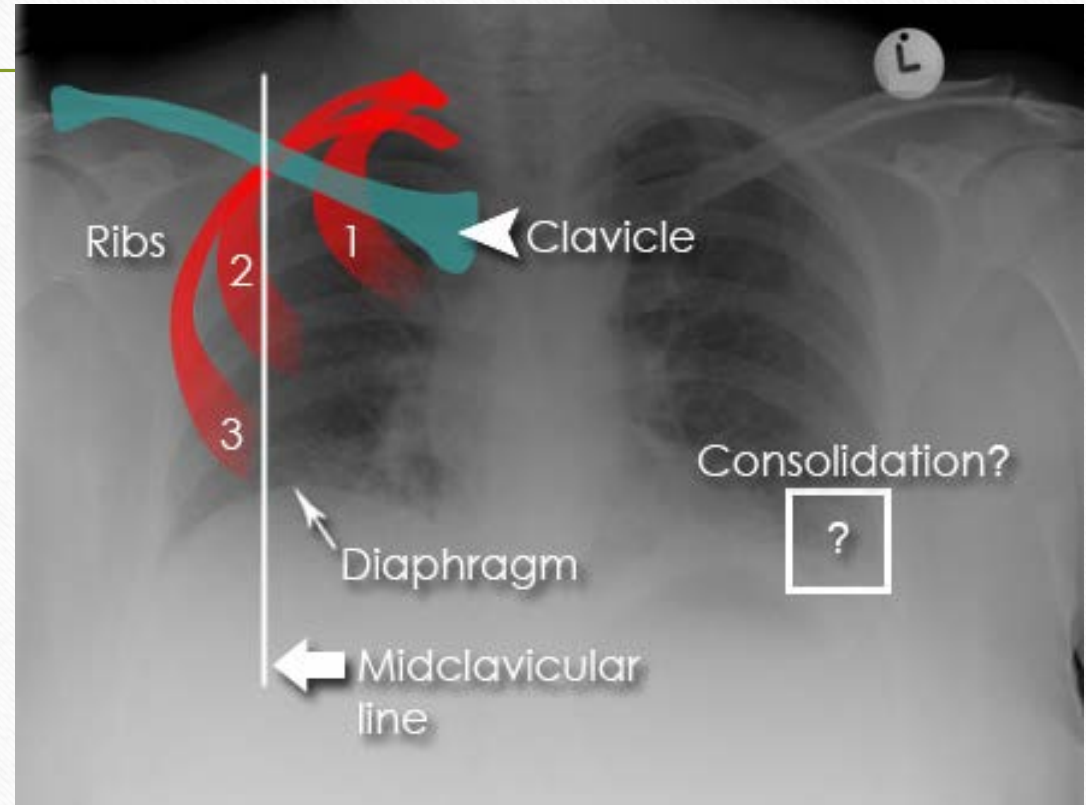
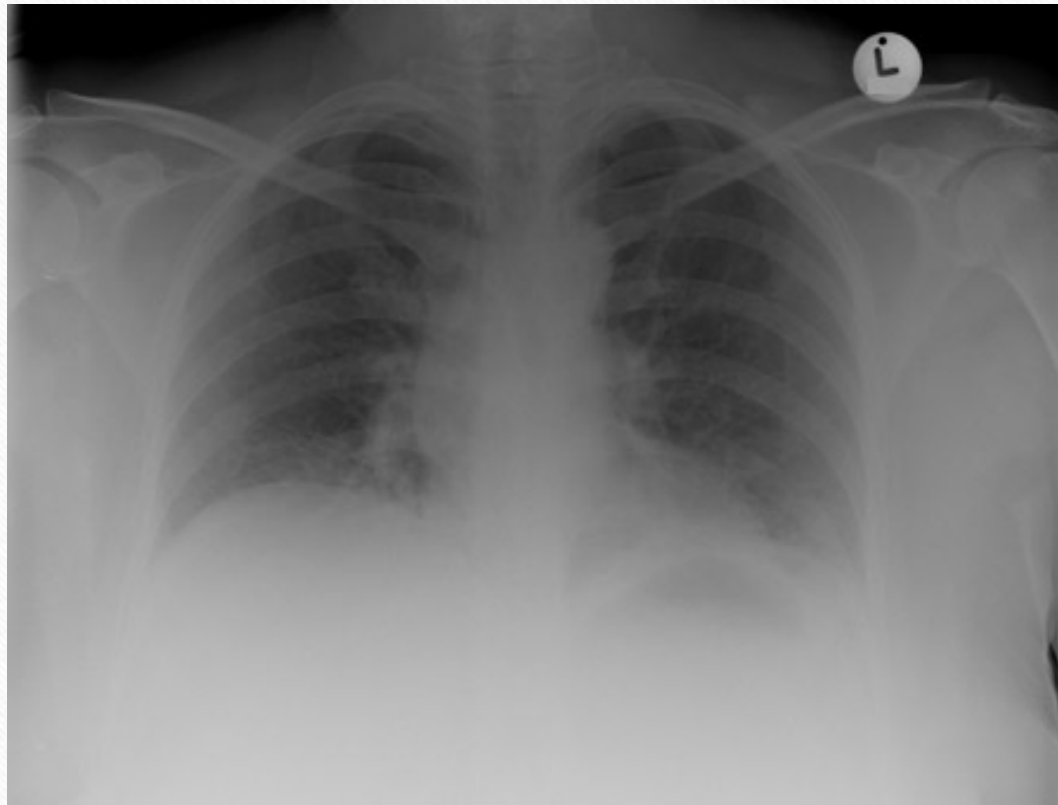
Assessment of Quality R.I.P.

- Rotation
 - Spinous processes should be midpoint between clavicles
- Inspiration
 - 5 – 7 costal spaces present at the midclavicular line
- Penetration
 - Can the spine be visualized behind the heart?

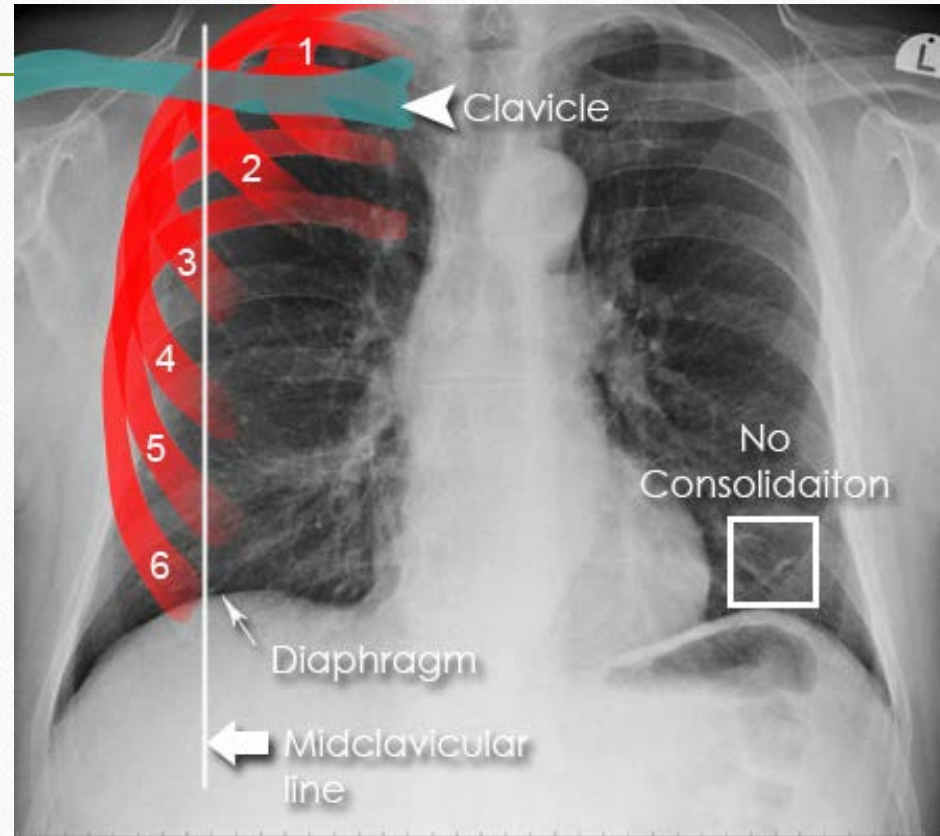
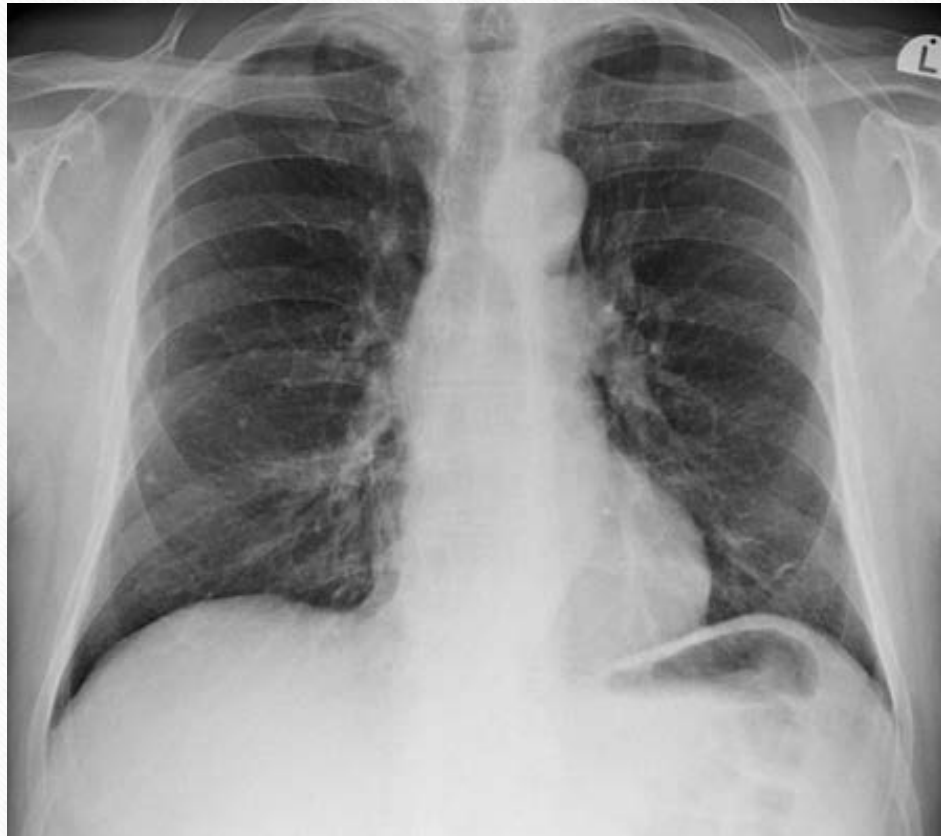Rotation



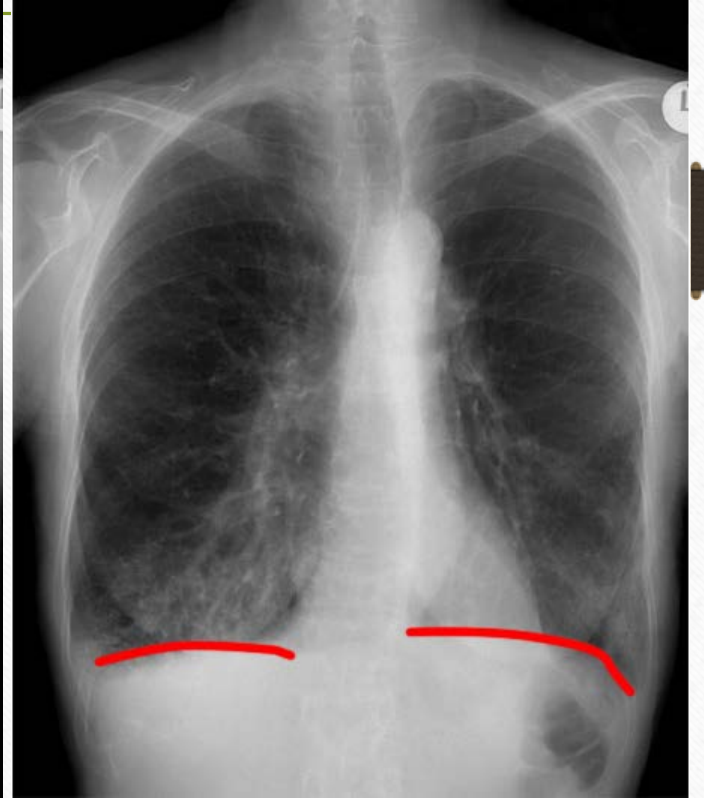
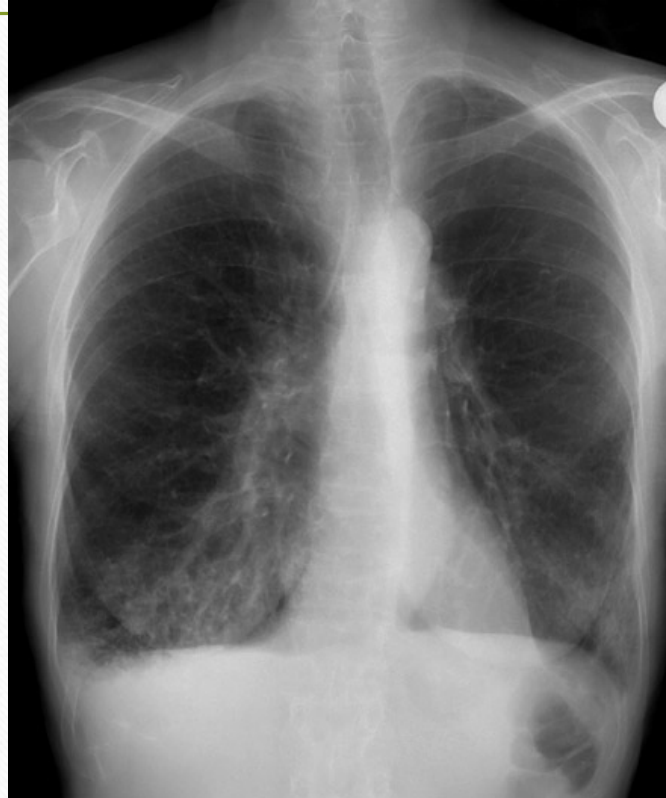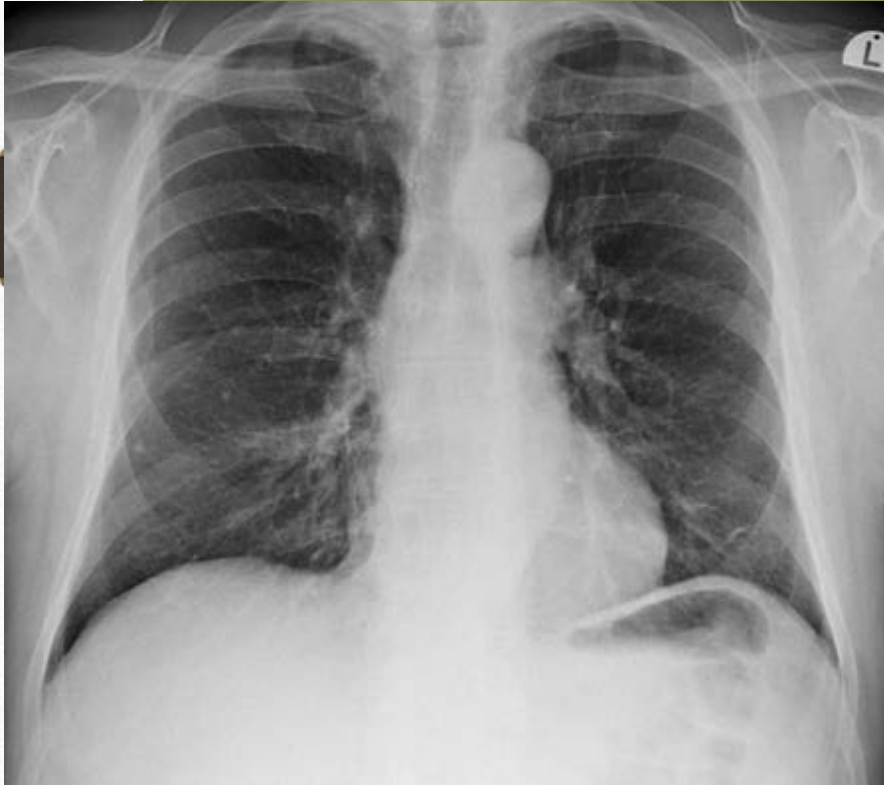Inspiration



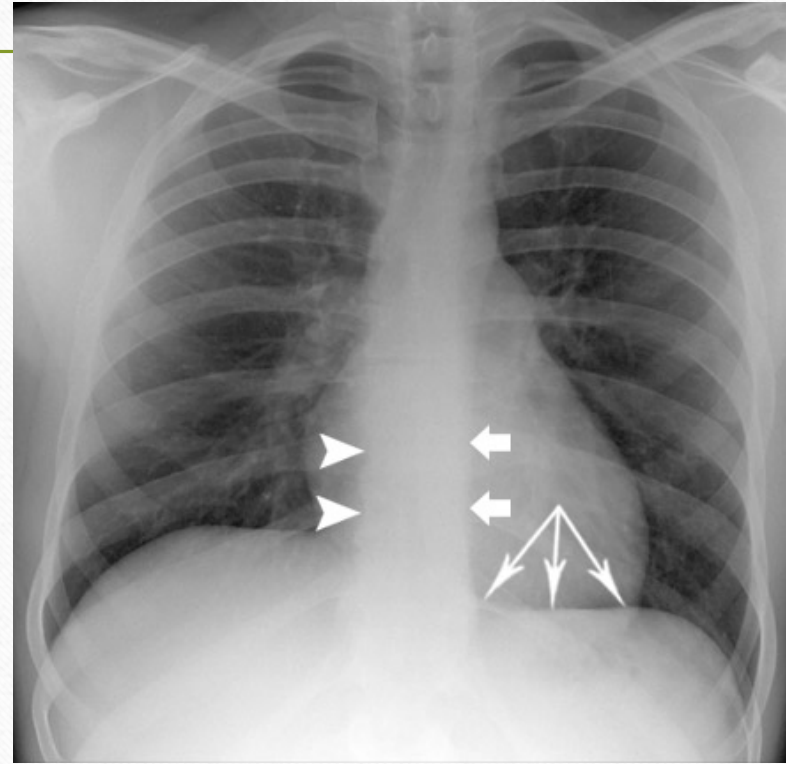
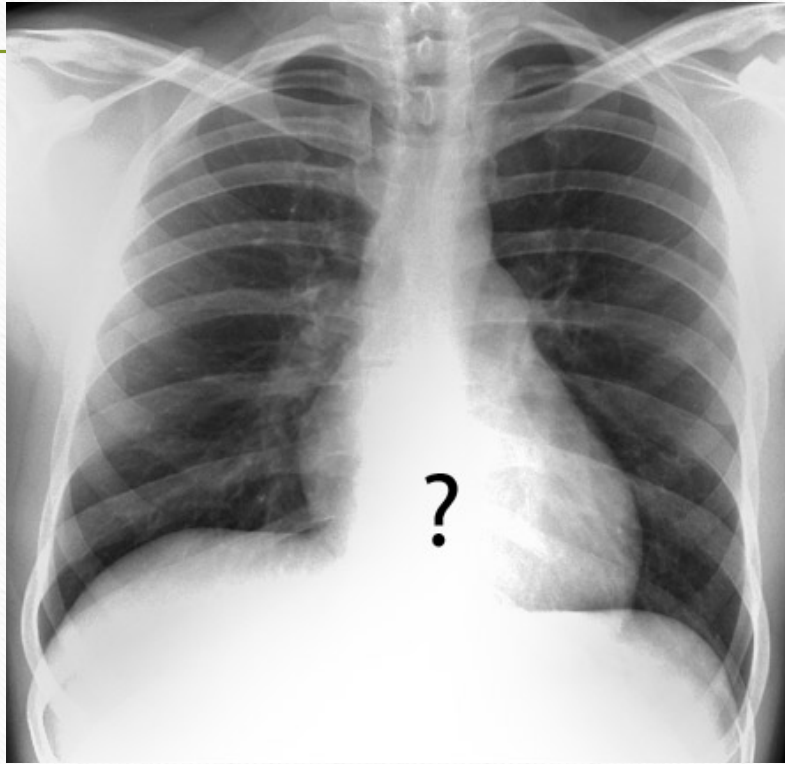
Inspiration



Expansion



Penetration

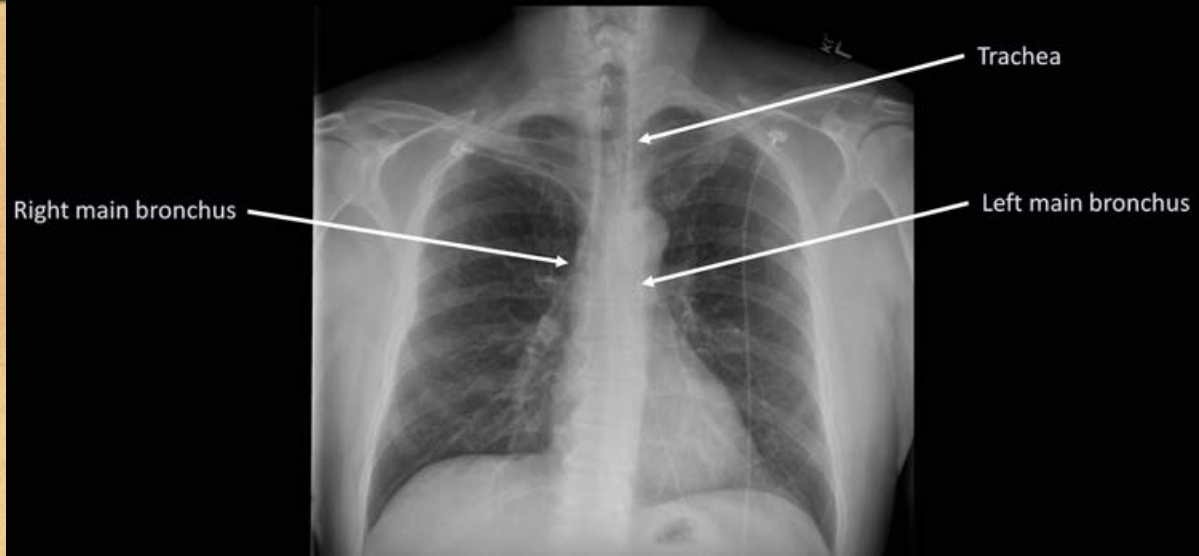

ABCDEF

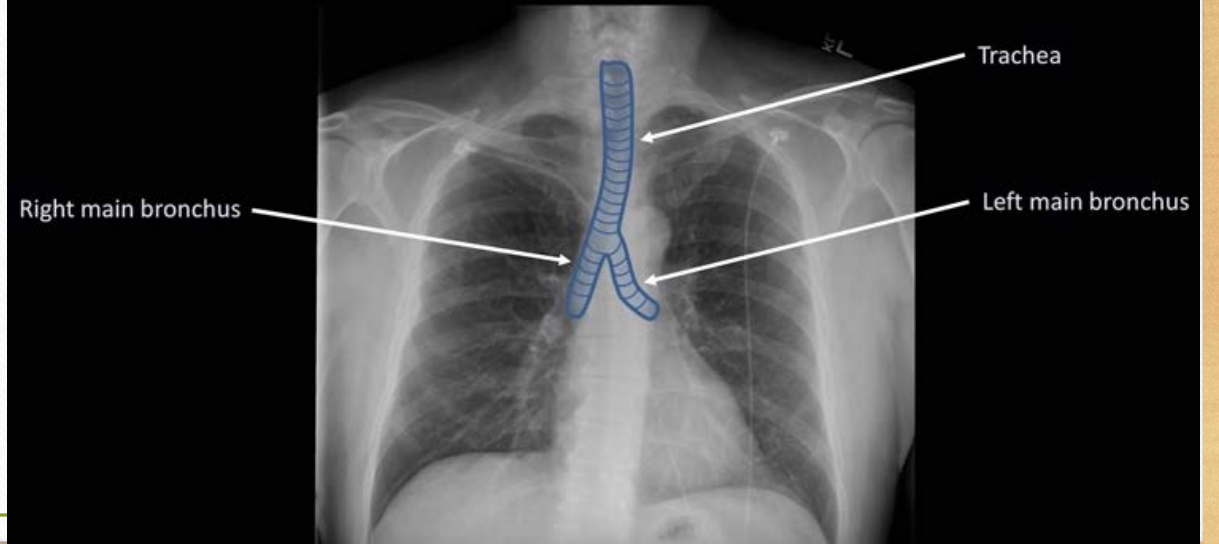
- Systematic approach to reading x-rays
 - **A**irway
 - **B**ones and soft tissue
 - **C**ardiac silhouette
 - **D**iaphragms
 - **E**ffusions
 - **F**ields

Airway

Anatomy - Airways

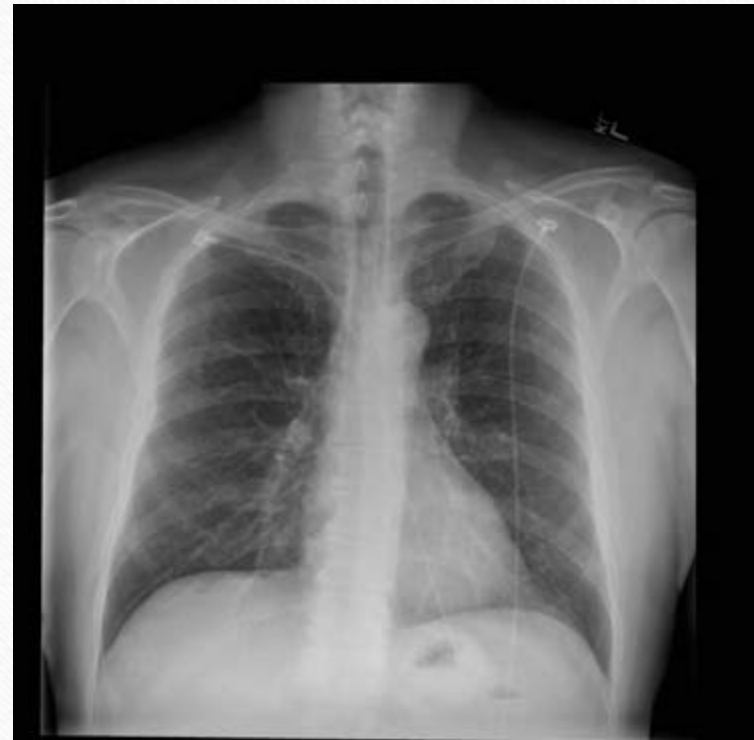

Anatomy - Airways



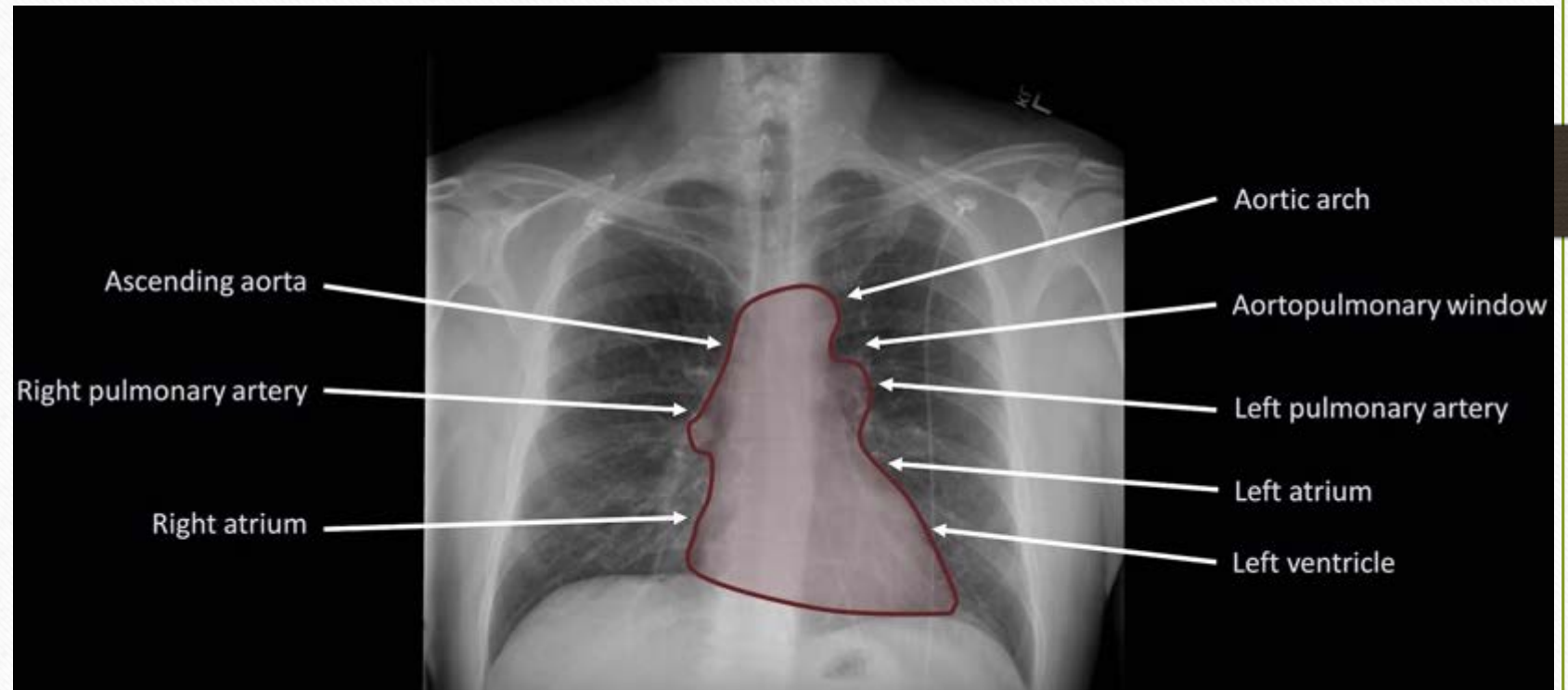
Bones

- 4 main bones to identify
 - Clavicle
 - Rib
 - Vertebral body
 - Sternum
 - Hard to discern



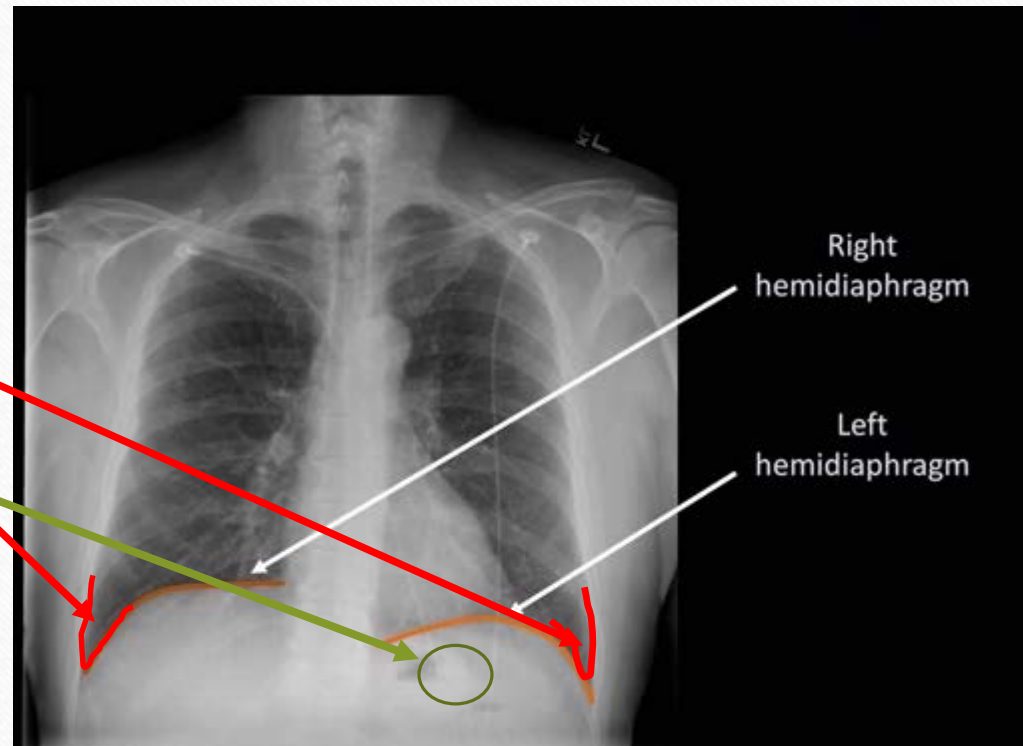
Cardiac Silhouette

- Mediastinum interpretation



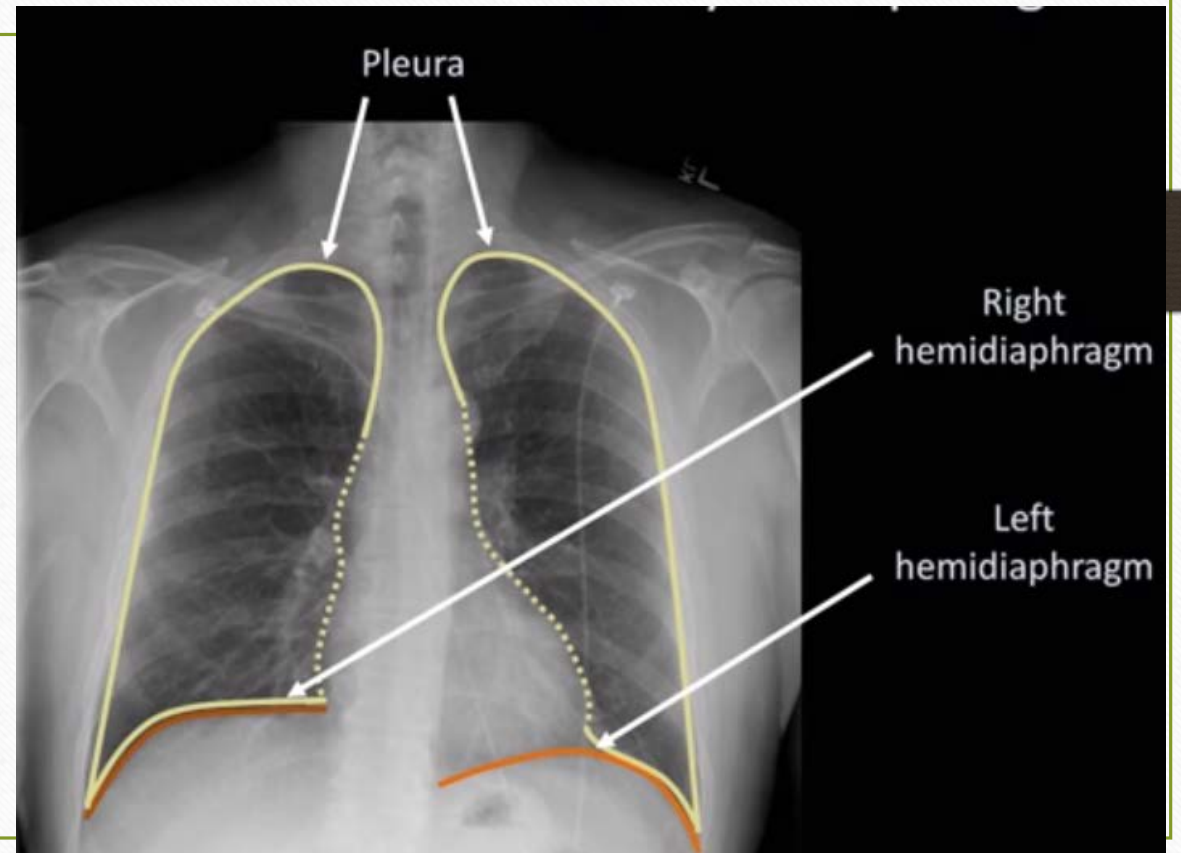
Diaphragm

- Right elevated by liver
- Costophrenic angle
- Gastric bubble

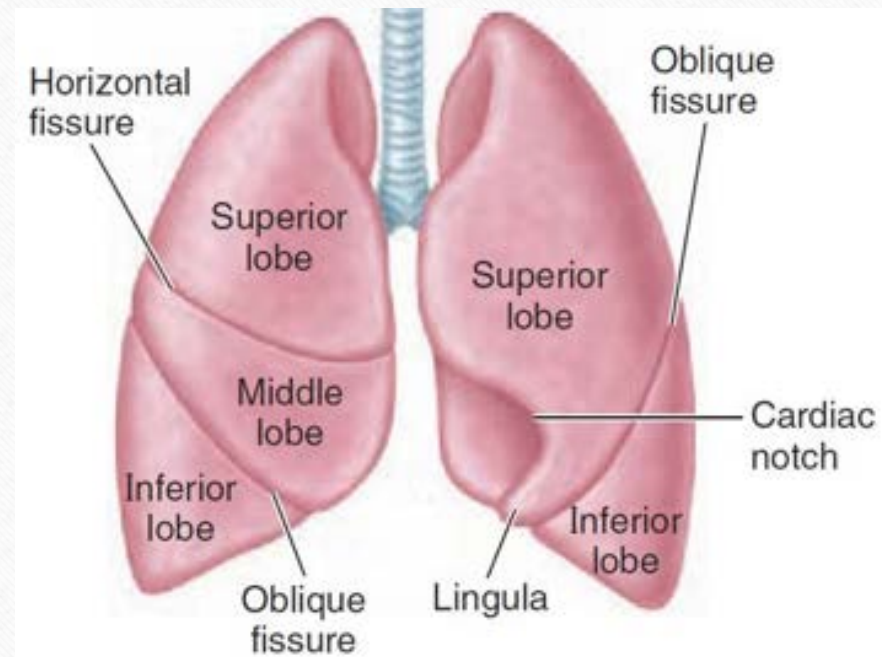


Effusions

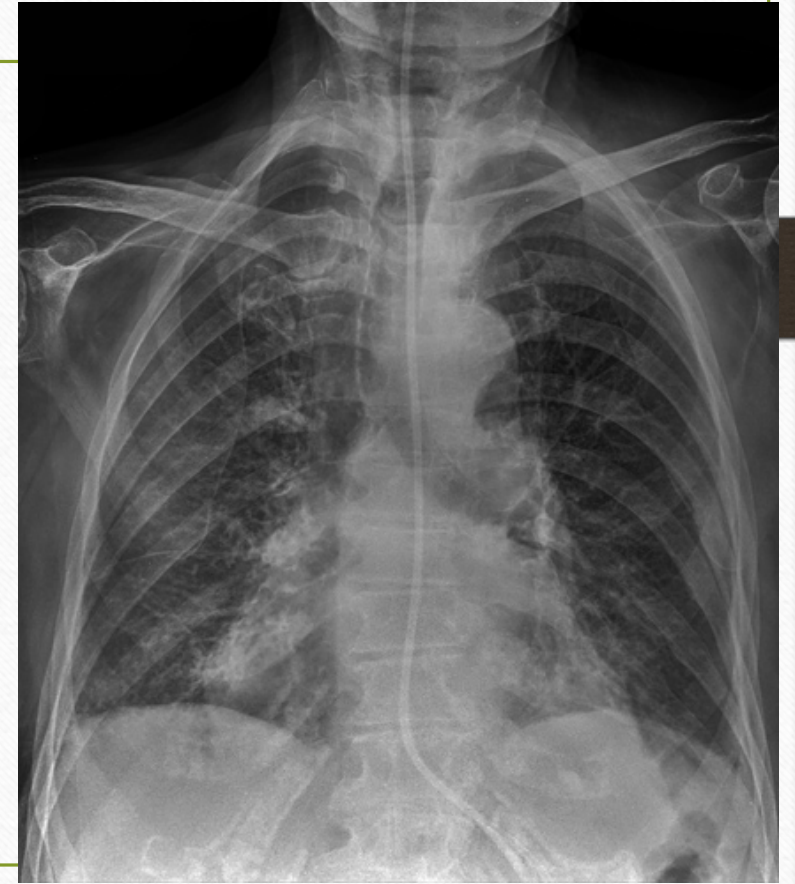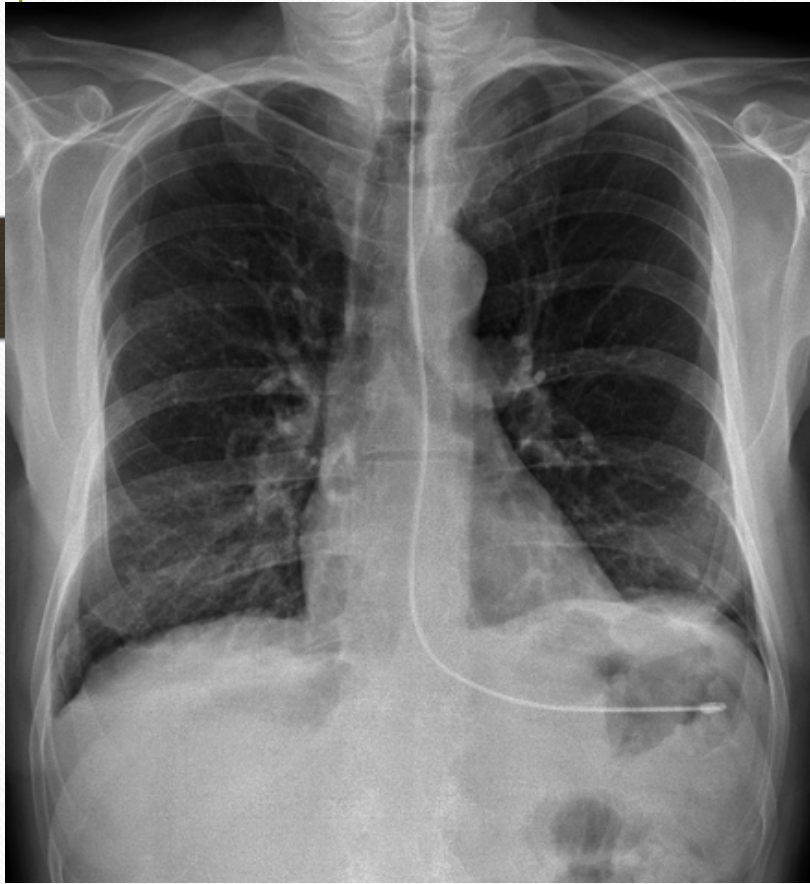
- Assess pleura to ensure full expansion.



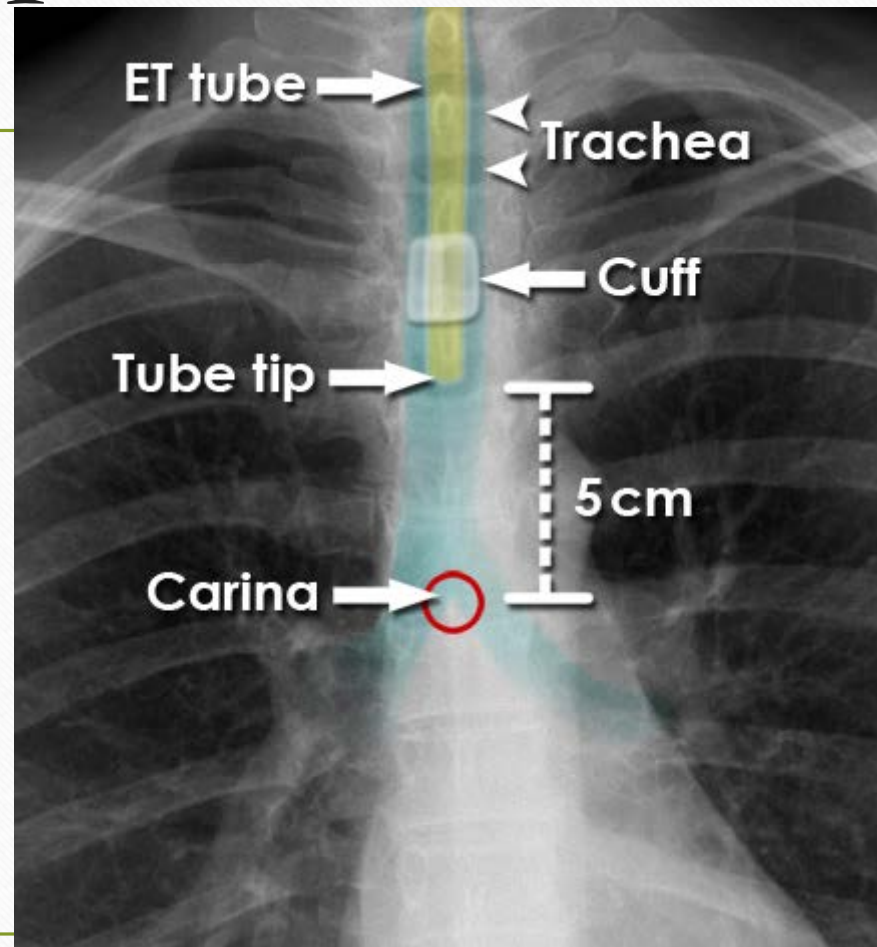
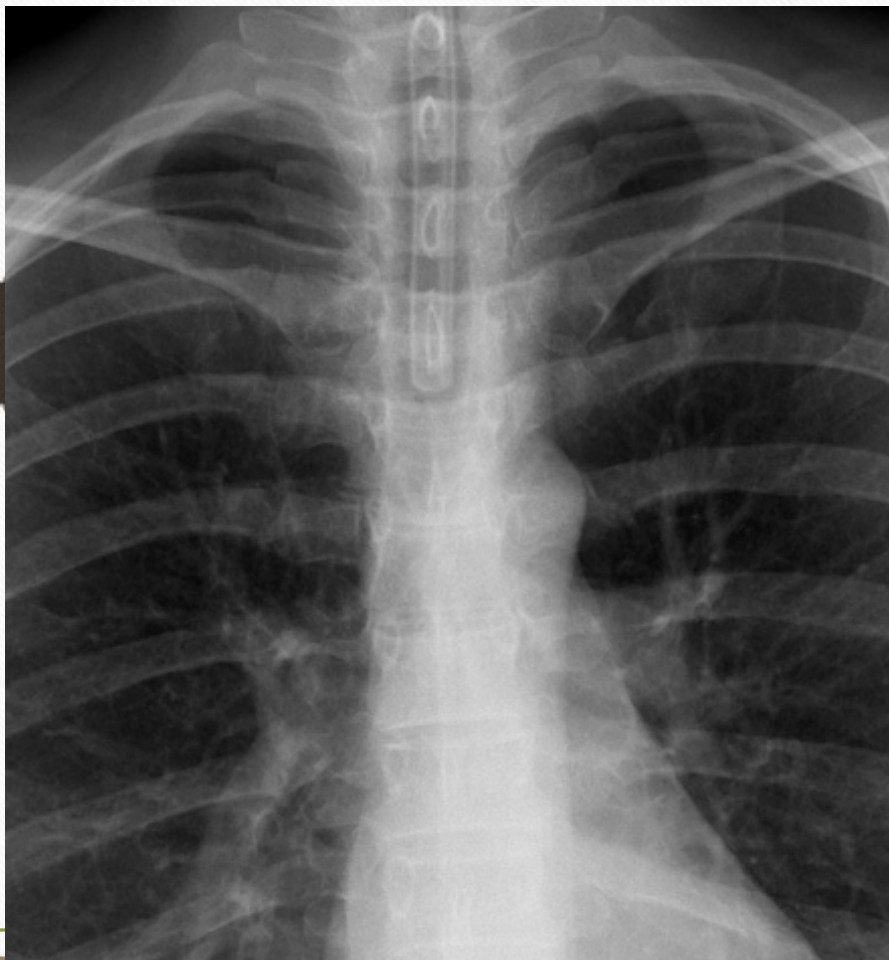Fields



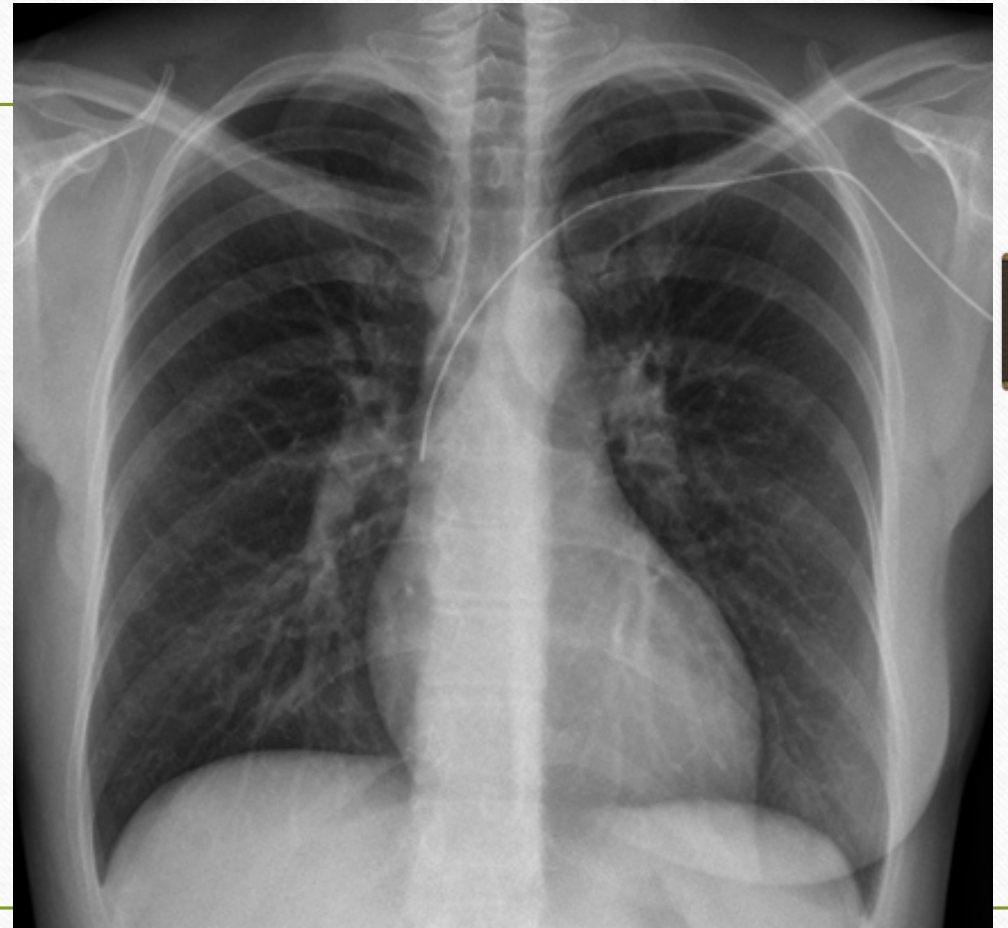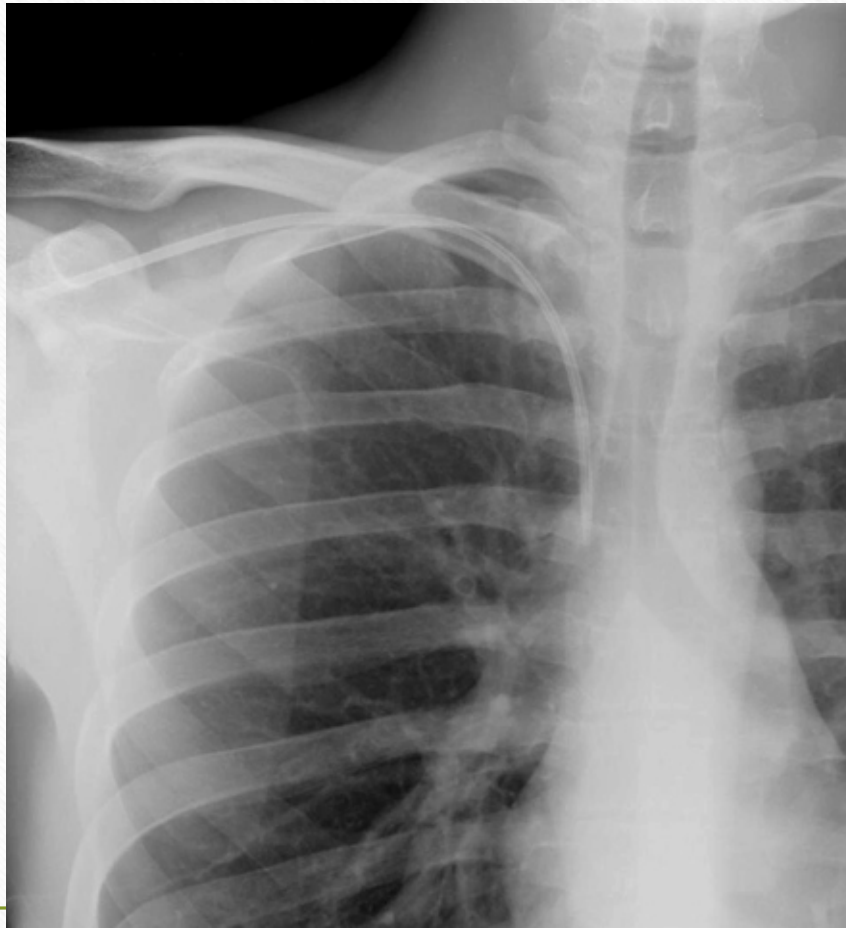Devices, Gastric Tubes



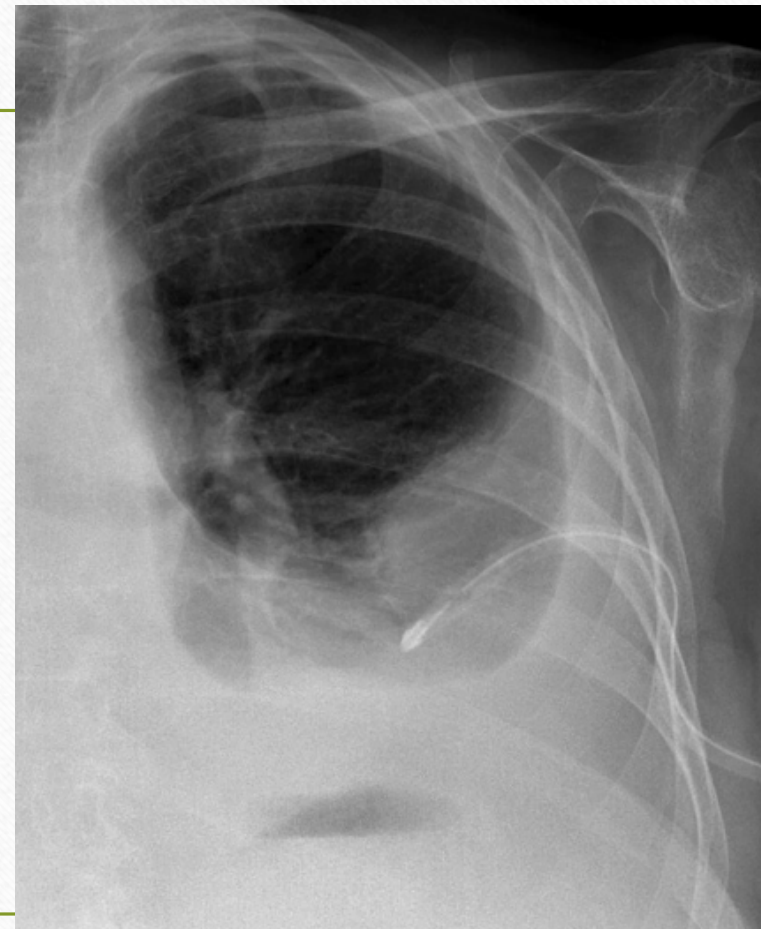
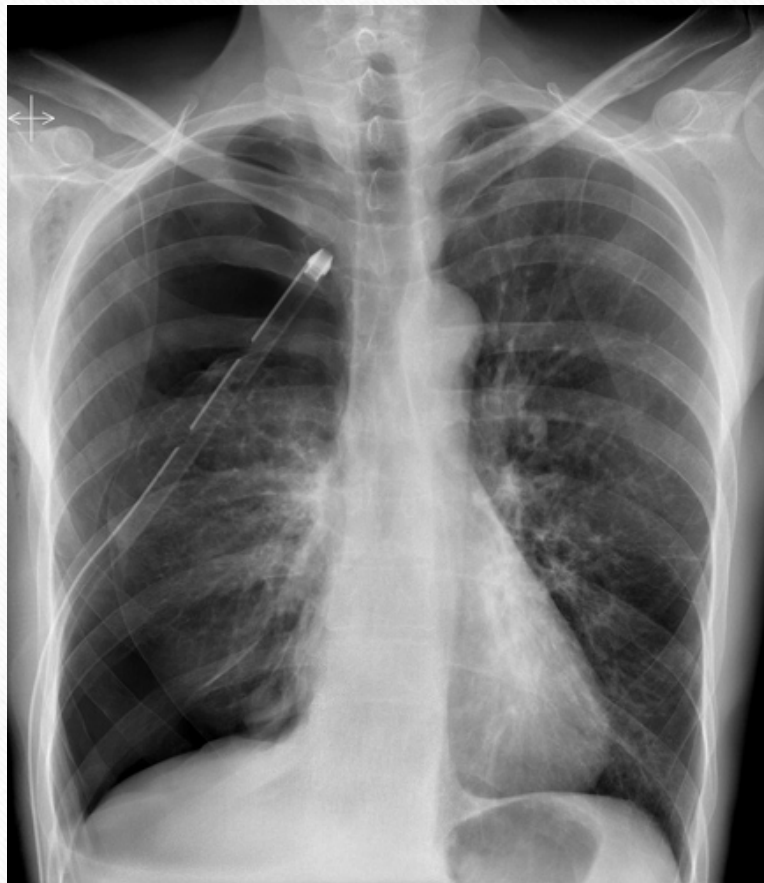Devices ETT



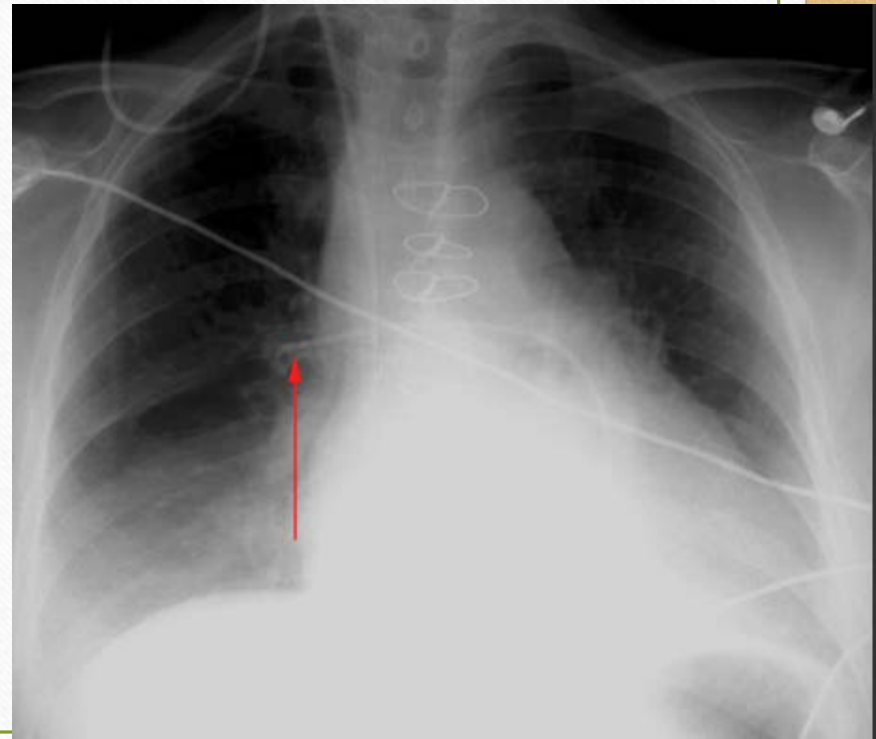
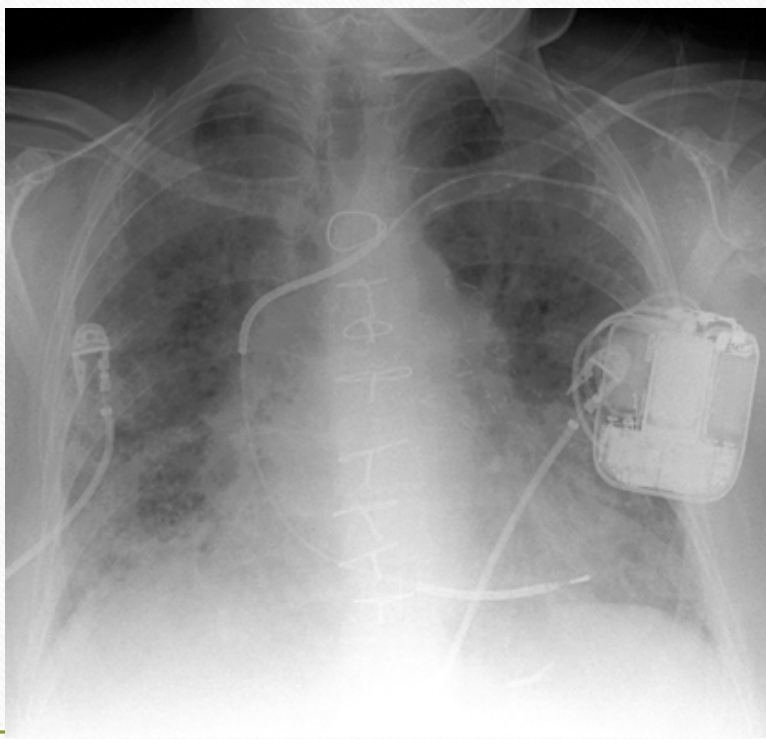
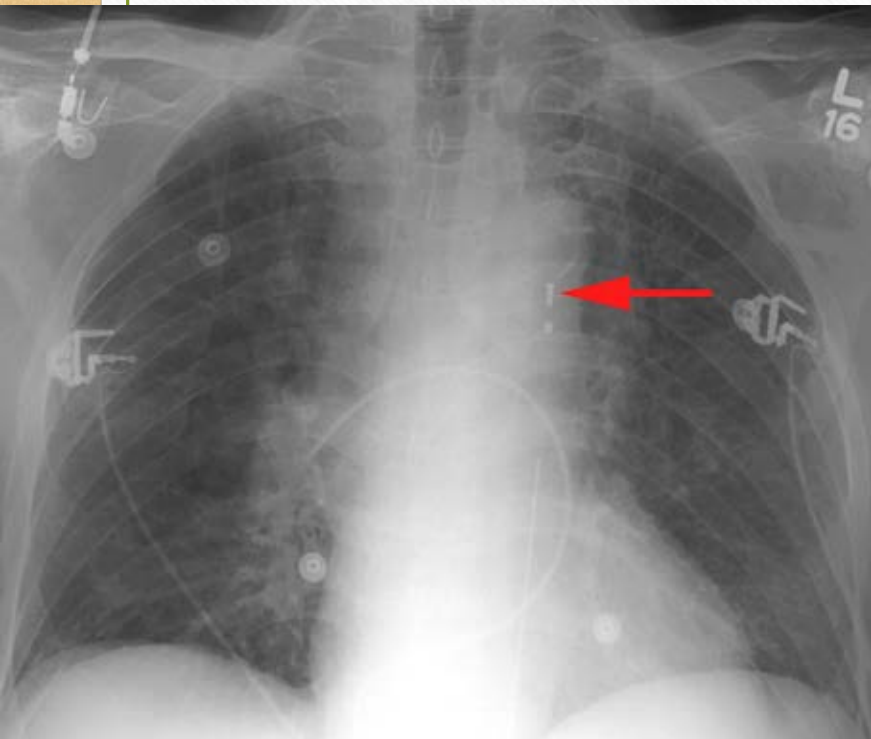
Devices CVL



Devices Chest Tubes

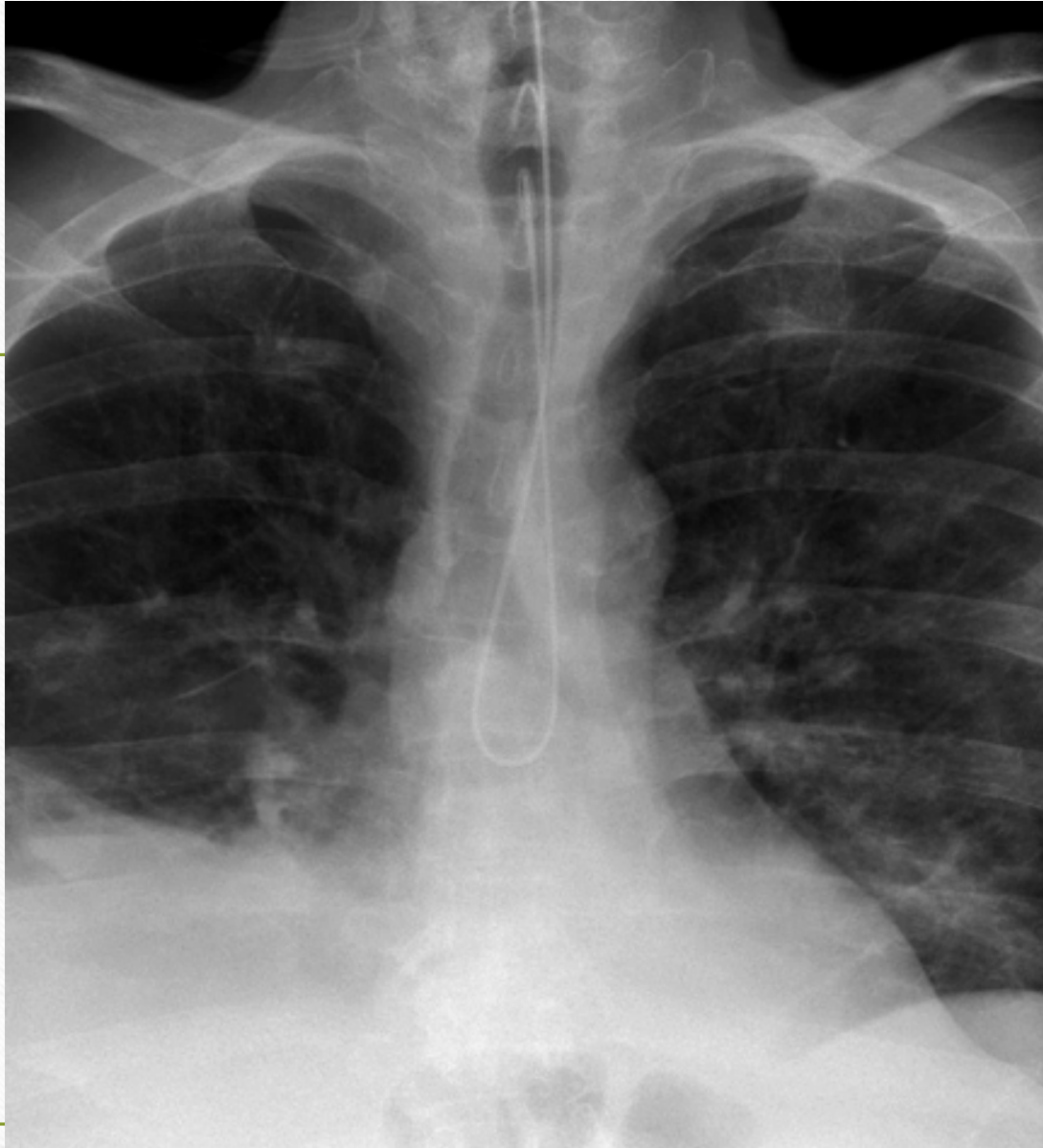

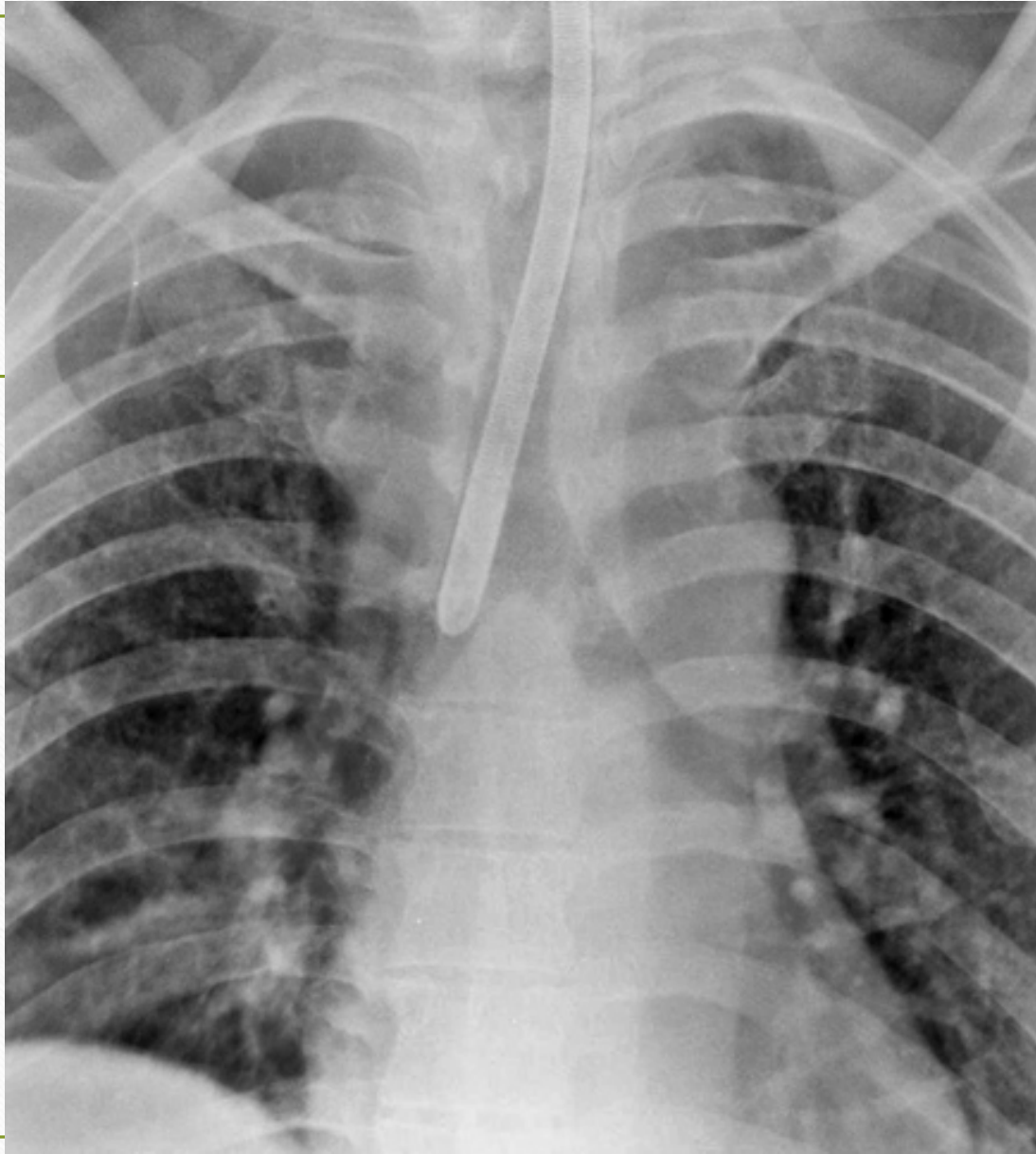
Devices-cardiac



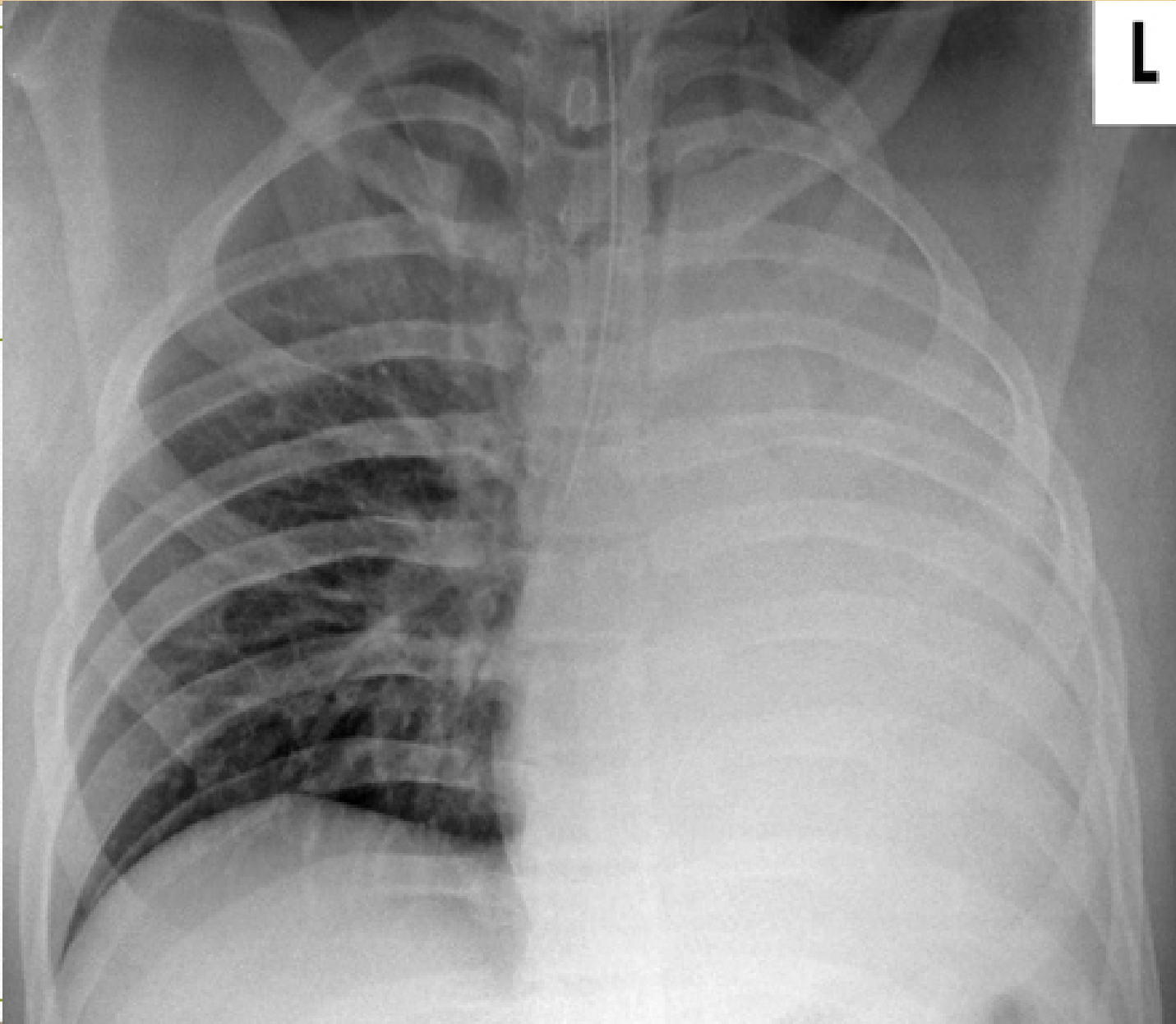
Test Time

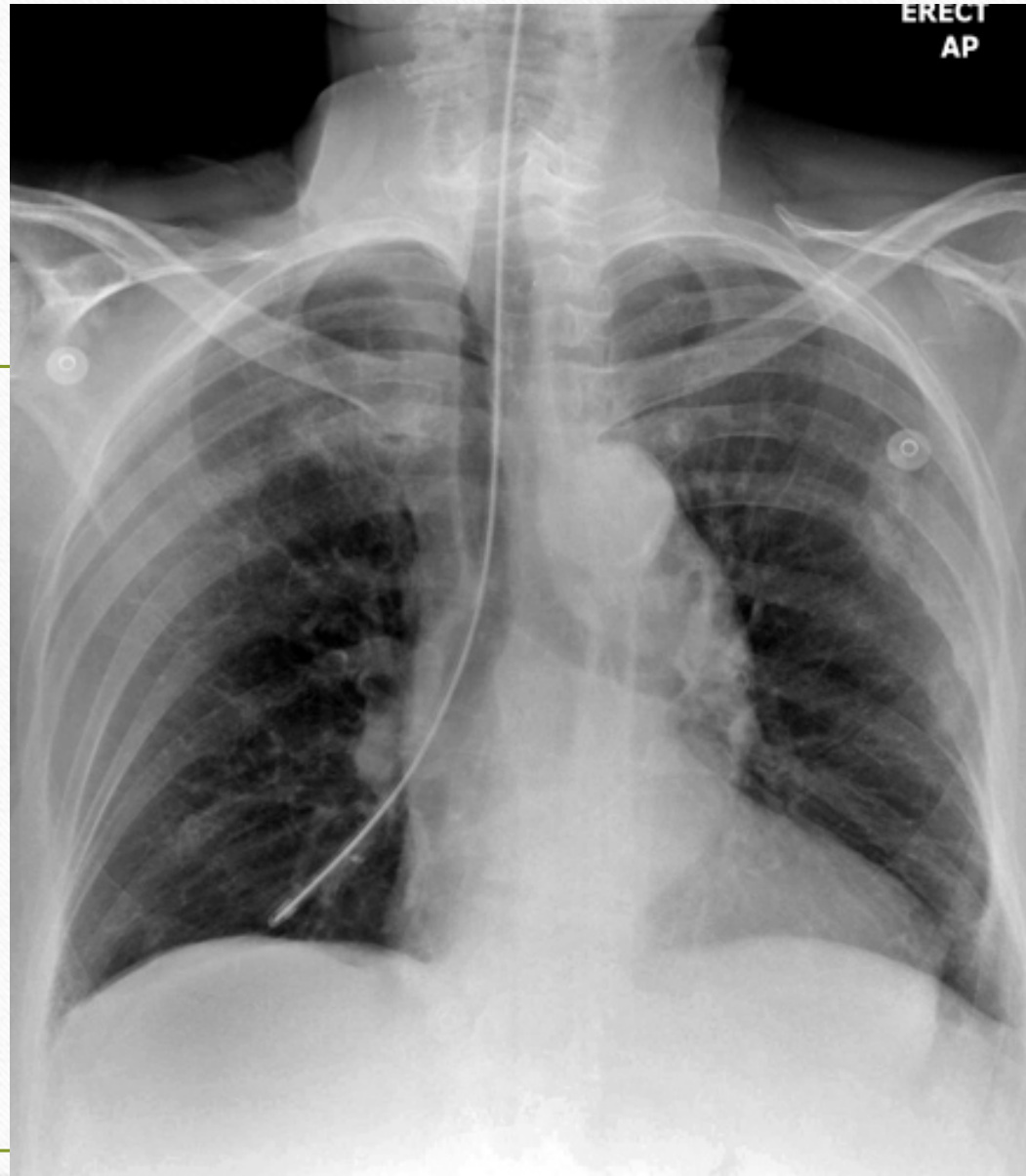

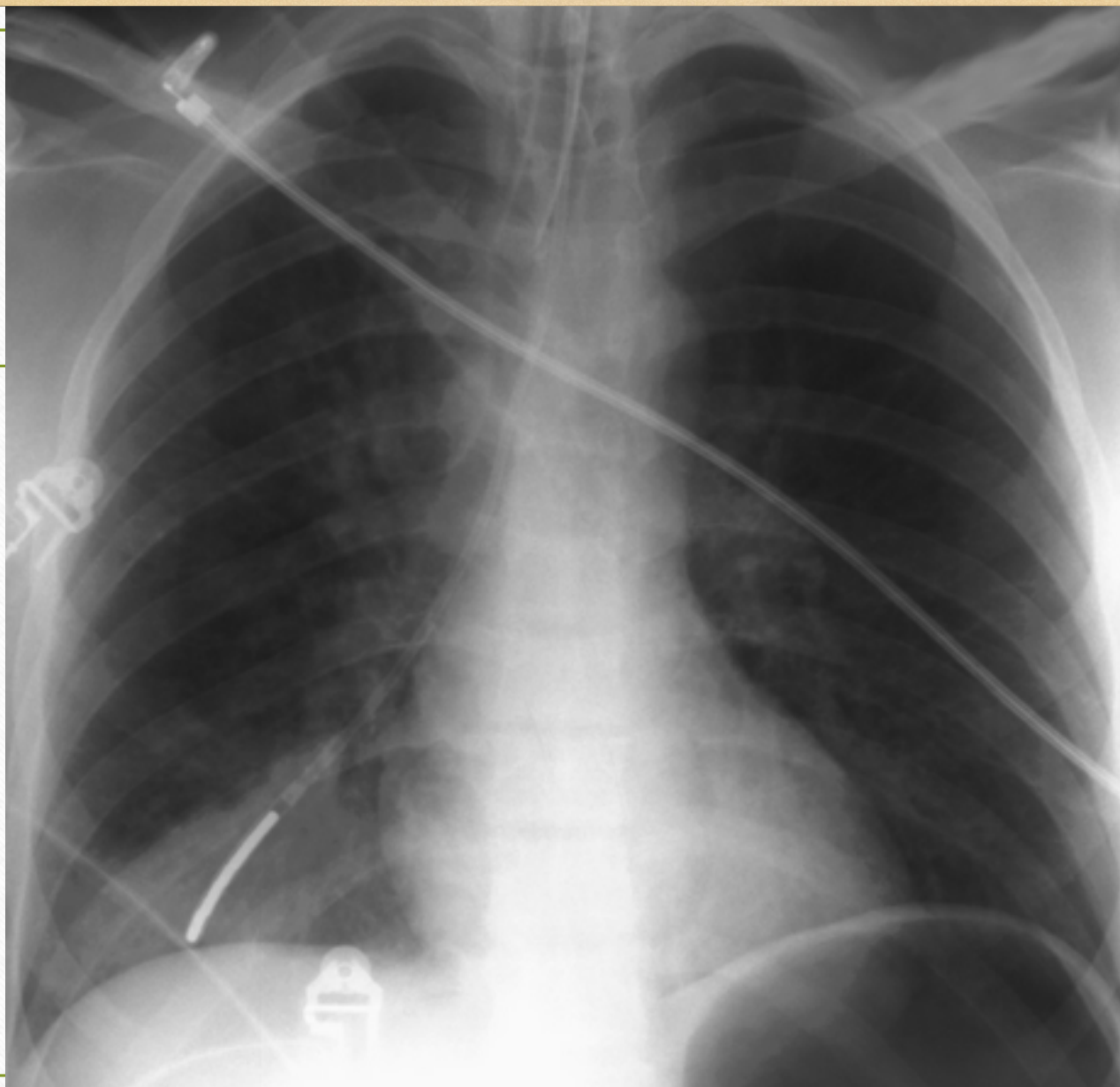


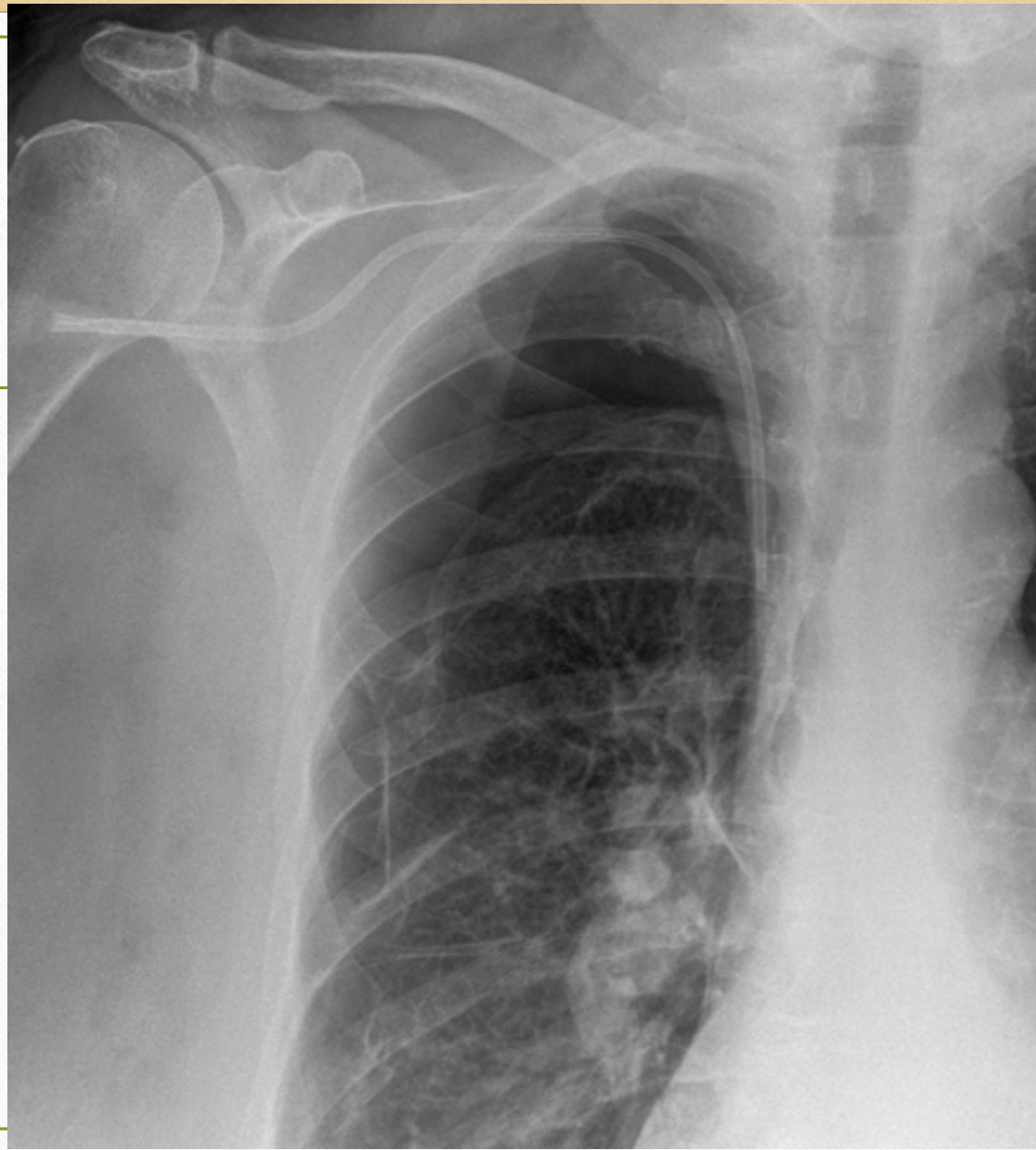


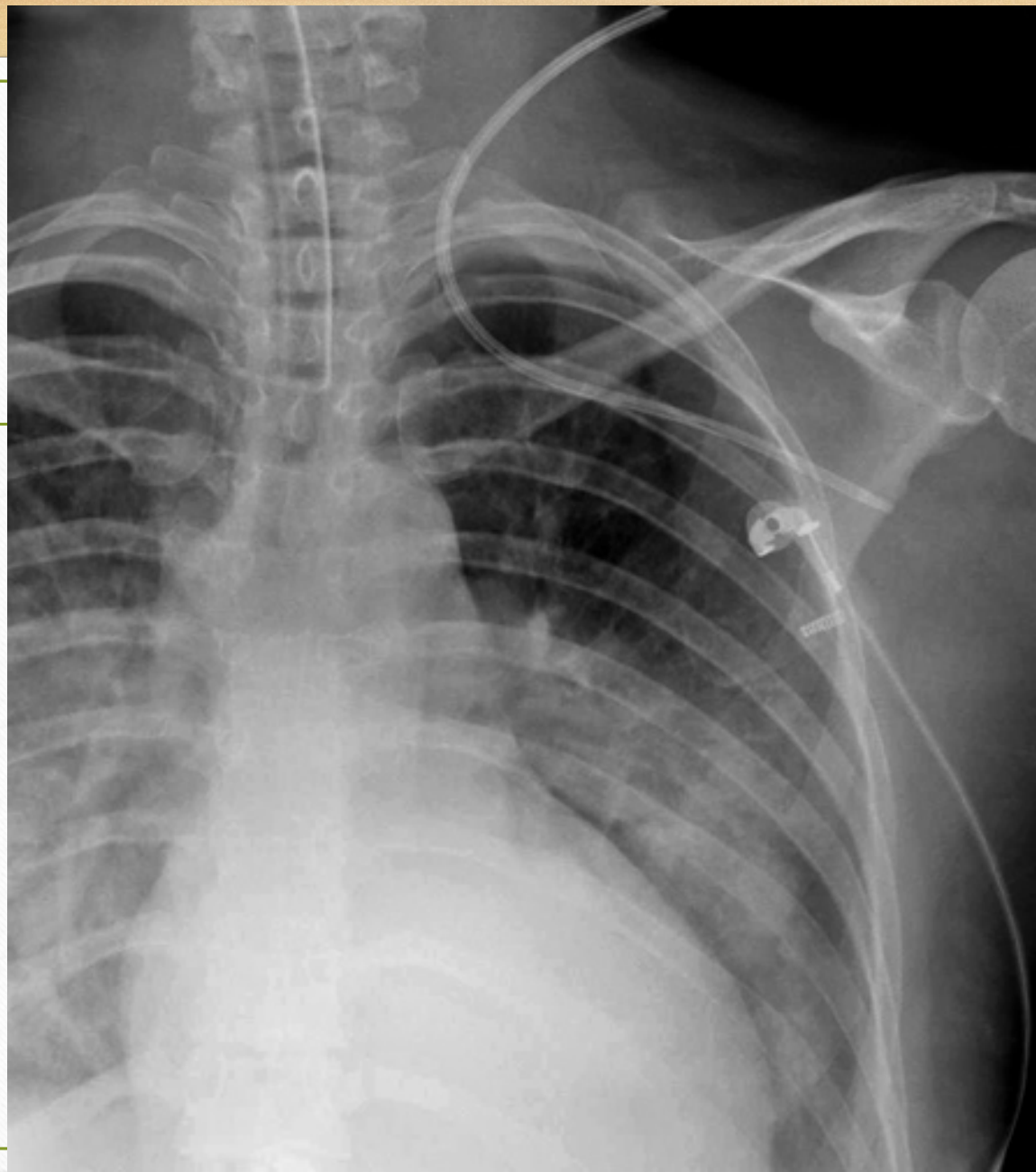
L

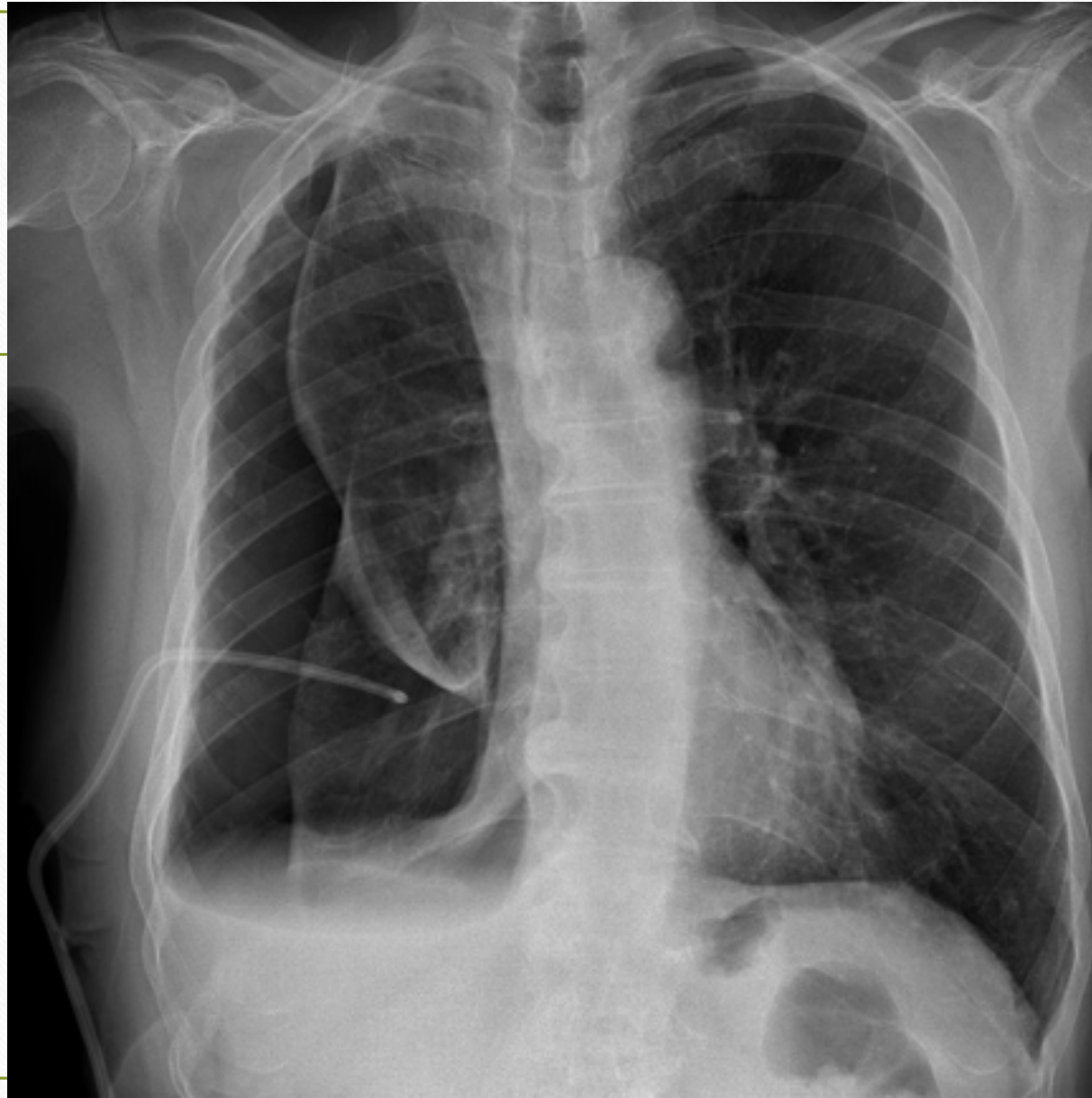


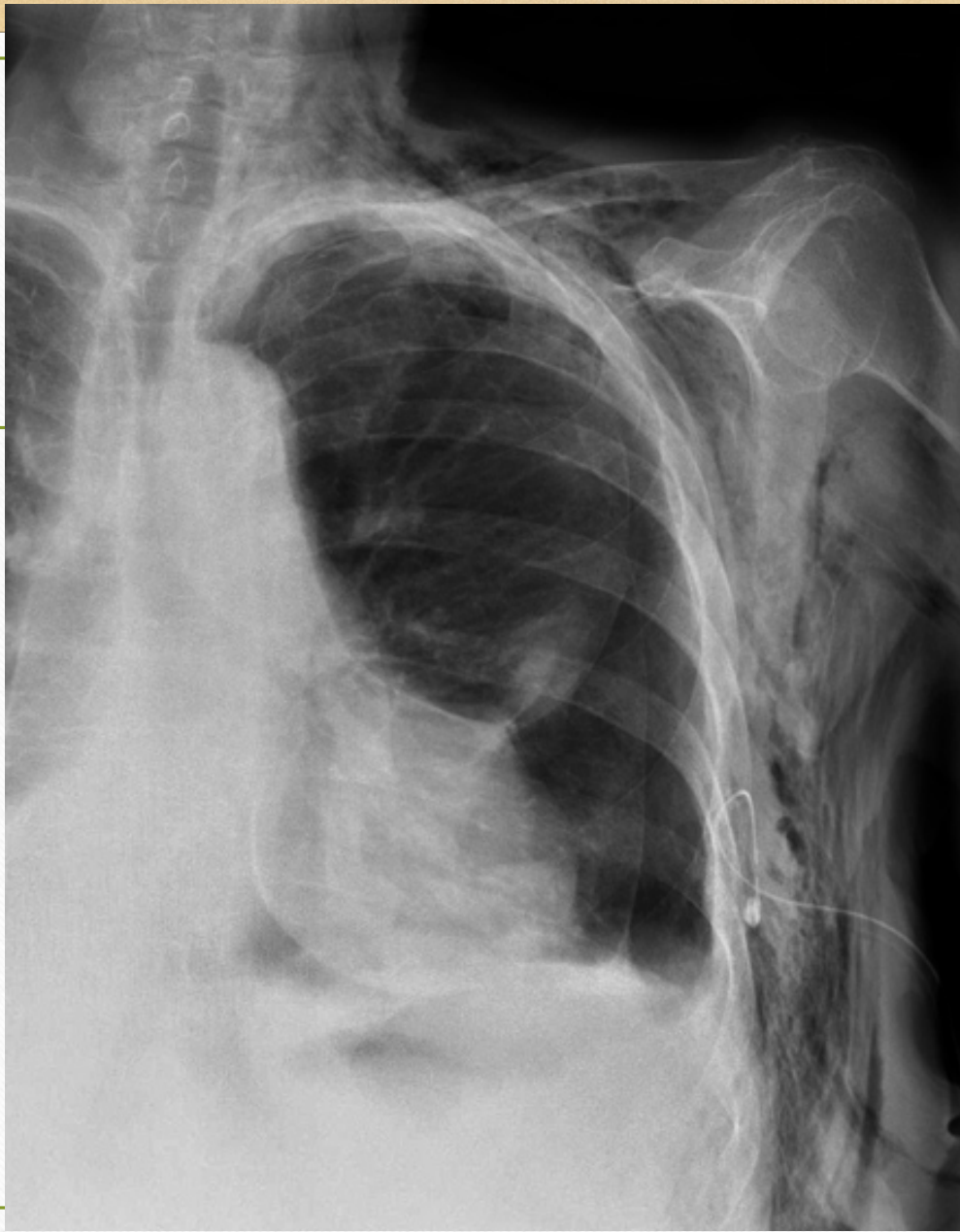


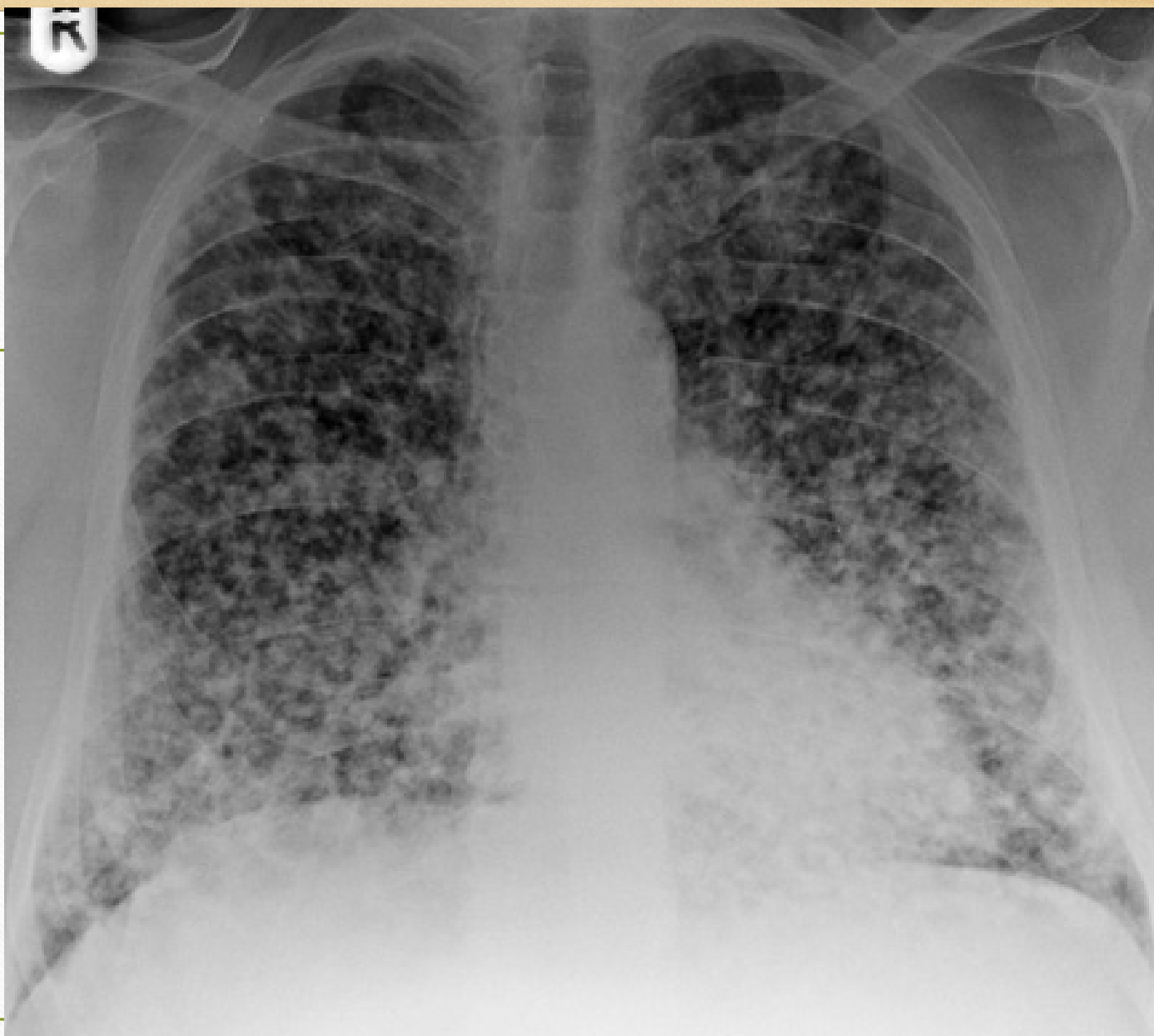





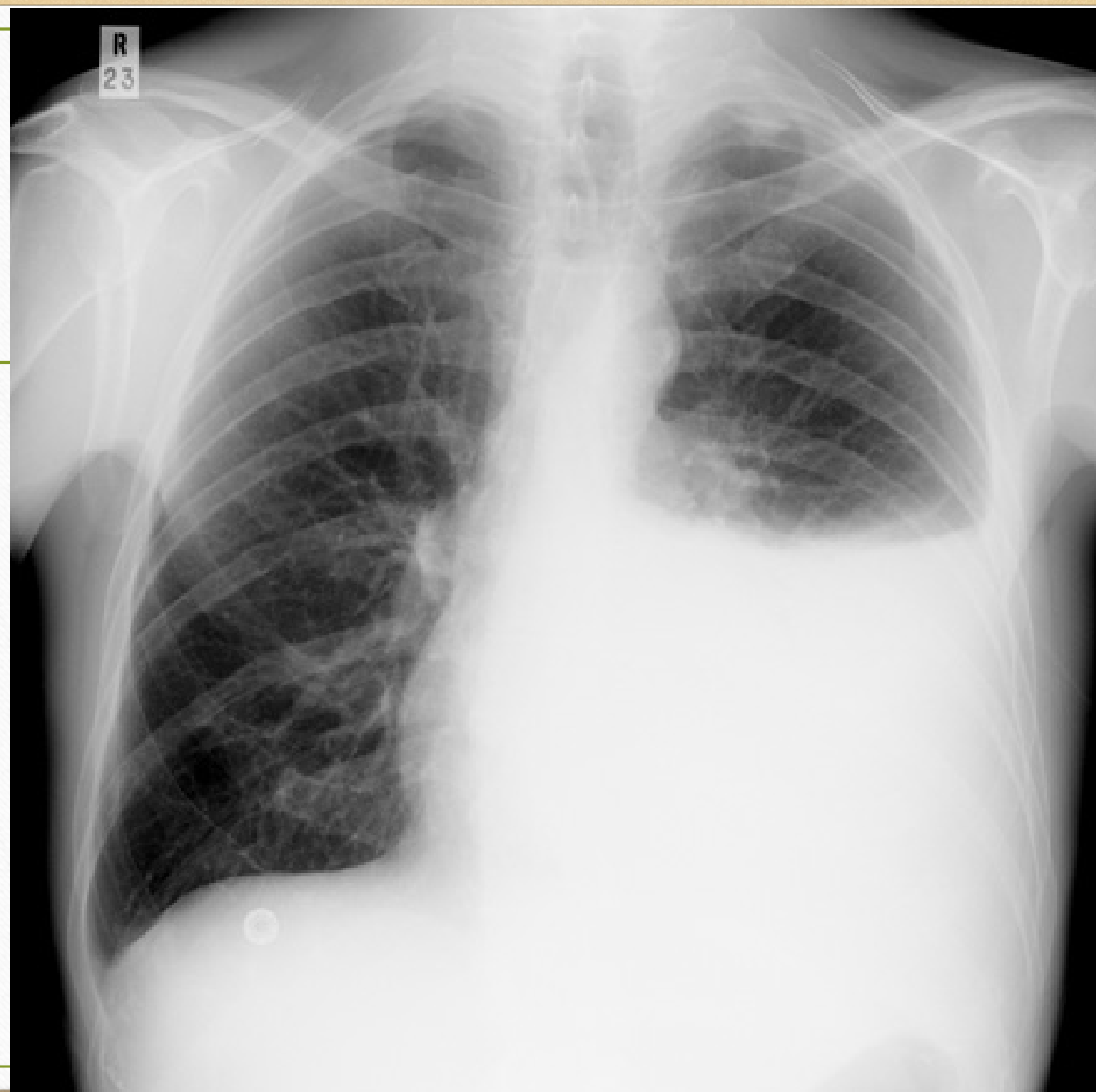



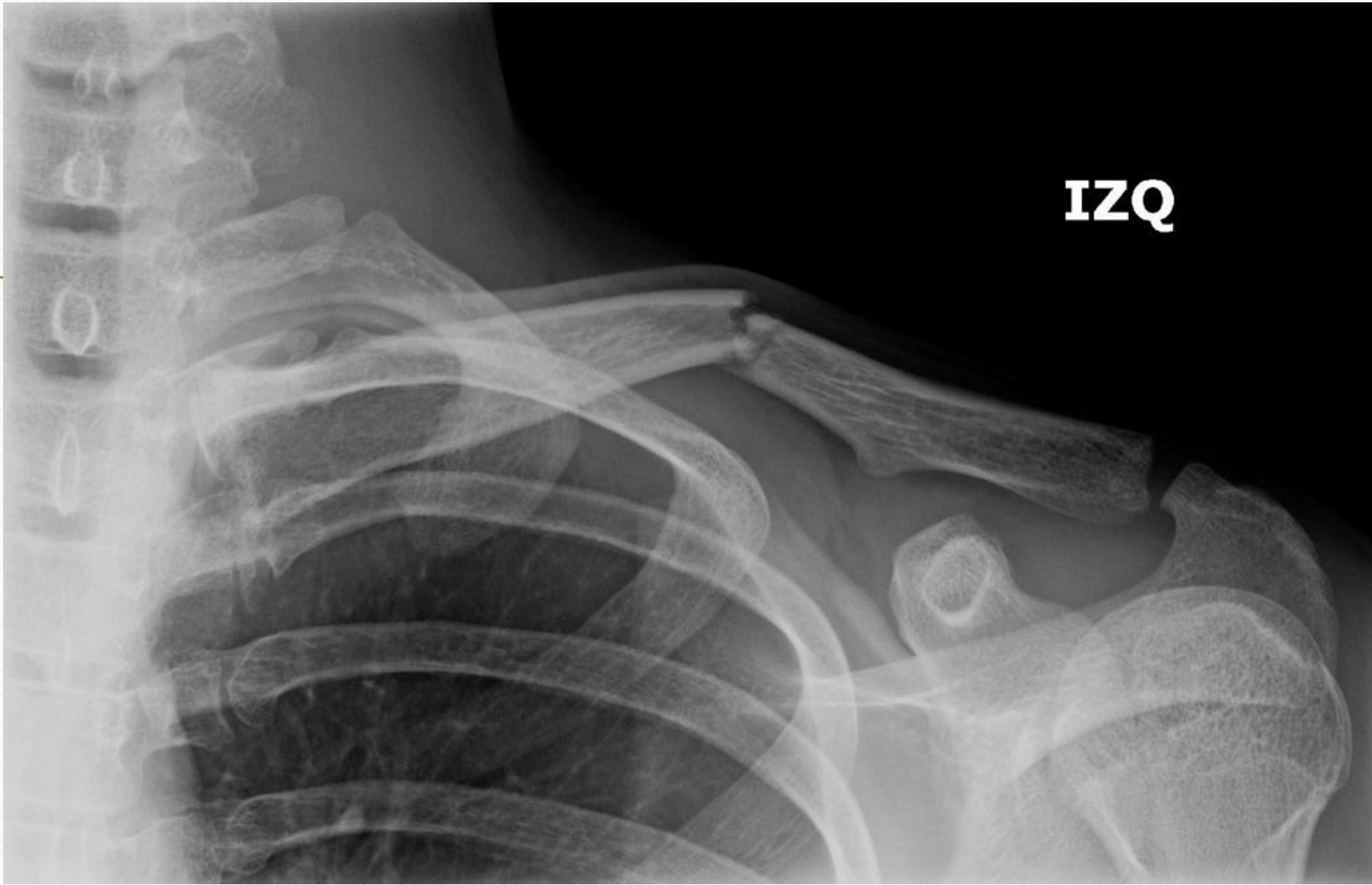


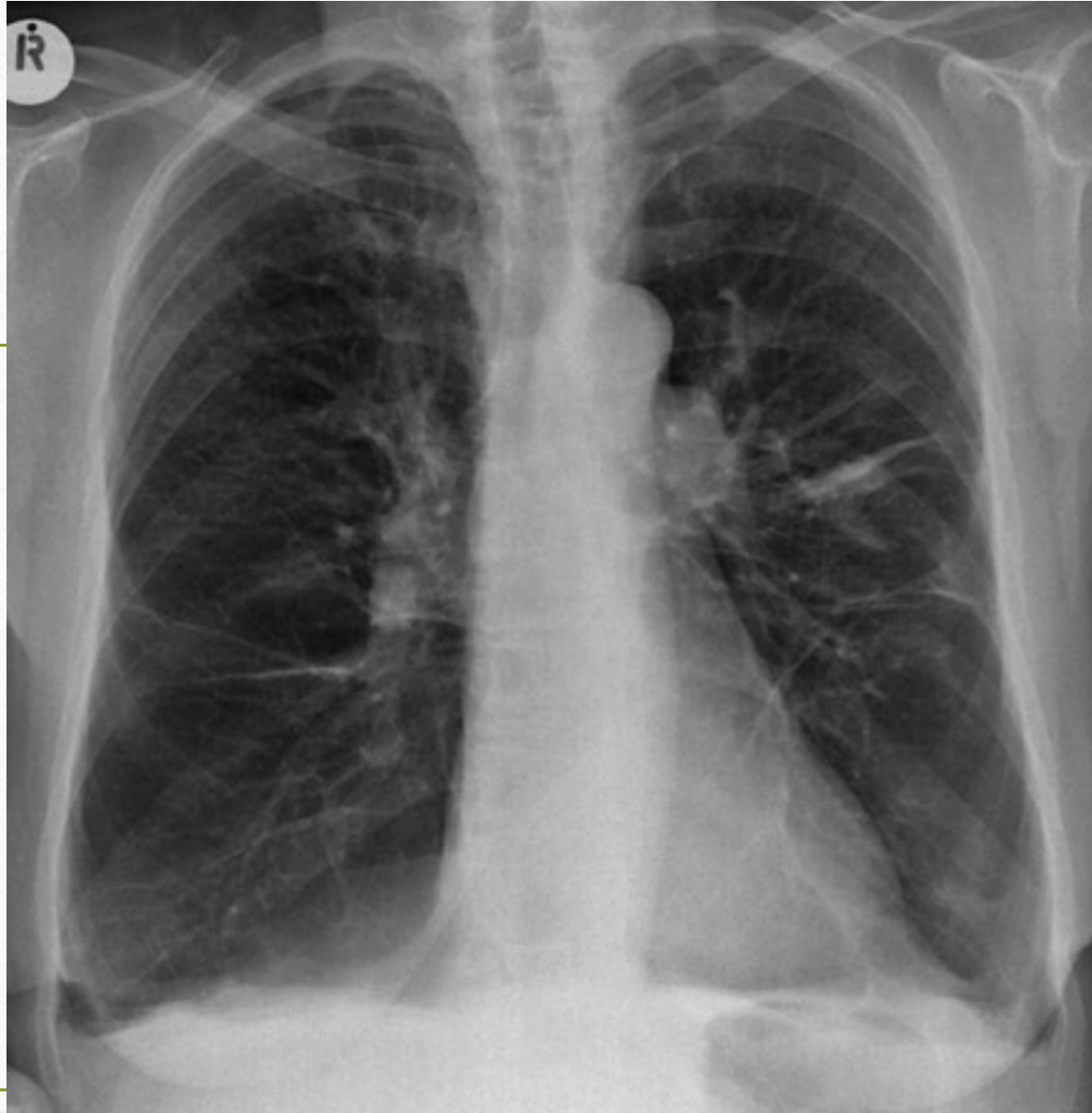
Blank white area for notes or annotations on the left side of the slide.

Blank white area for notes or annotations on the right side of the slide.



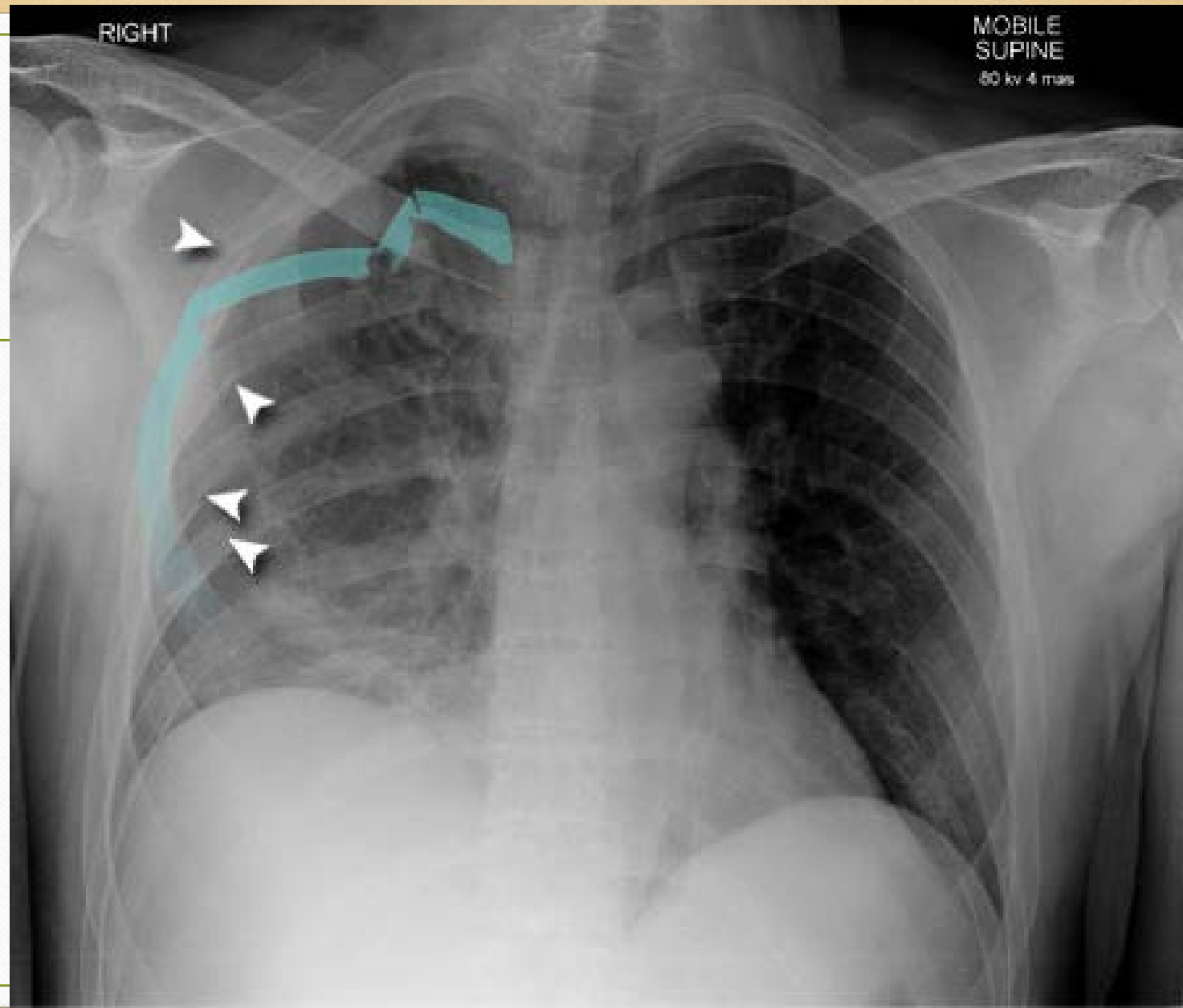


IZQ



RIGHT

MOBILE
SUPINE
80 kv 4 mas



References

- All pictures courtesy of
 - Radiopaedia.org
 - Radiologymasterclass.com.uk
 - University of Virginia
 - Sharon Dickinson MSN, CNS, NP, CCRN University of Michigan Medical Center
- Brant, W., Helms, C., *Fundamentals of Diagnostic Radiology*(4th ed.). Lippincott Williams & Wilkins, Philadelphia PA, 2012.
- Mettler, F., *Essentials of Radiology*(3rd ed.). El Sevier, Philadelphia PA. 2014